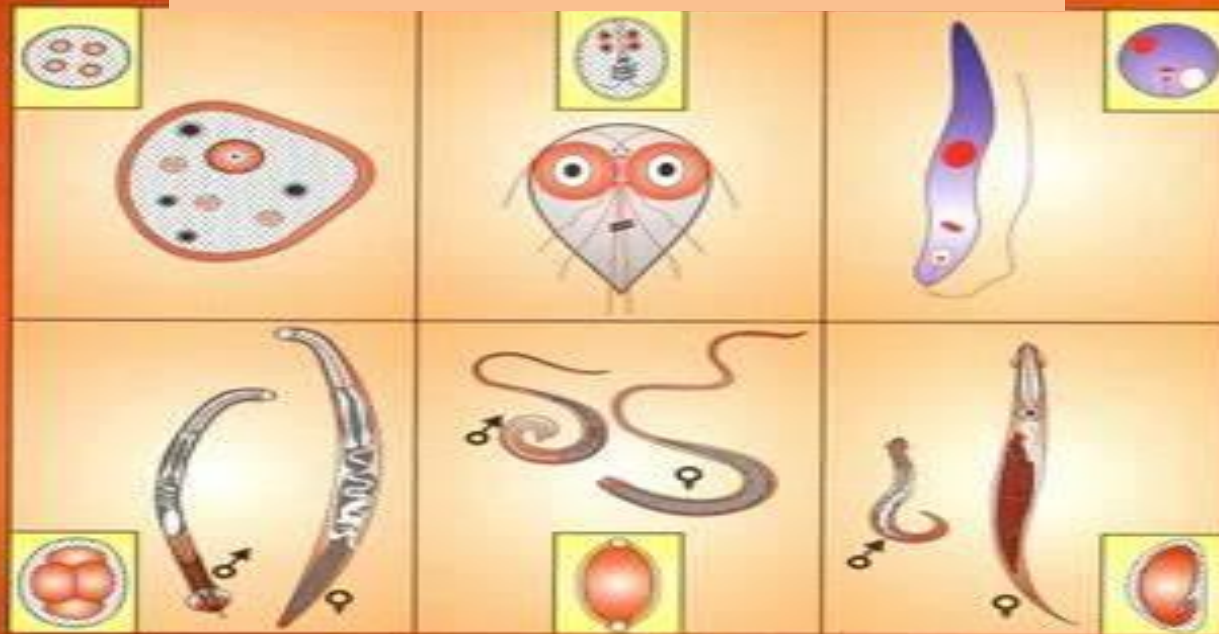


MEDICAL PARASITOLOGY

lec.10: Nematodes



Assist. Prof. Dr. Maysam Adnan Mezher

III- Introduction : Nematodes

Nematodes are round-worms with a cylindrical body and a complete digestive tract, including a mouth and an anus. The body is covered with a noncellular, highly resistant coating called a cuticle. Nematodes have separate sexes; the female is usually larger than the male. The male typically has a coiled tail. The medically important nematodes can be divided into two categories according to their primary location in the body, namely, **intestinal** and **tissue** nematodes.

(1) **The intestinal nematodes** include *Enterobius* (pinworm), *Trichuris* (whipworm), *Ascaris* (giant roundworm), *Necator* and *Ancylostoma* (the two hookworms), *Strongyloides* (small roundworm), and *Trichinella*. *Enterobius*, *Trichuris*, and *Ascaris* are transmitted by ingestion of eggs; the others are transmitted as larvae.

There are two larval forms: the first- and second-stage (**rhabditiform**) larvae are noninfectious, feeding forms; the third-stage (**filariiform**) larvae are the infectious, nonfeeding forms. As adults, these nematodes live within the human body, except for *Strongyloides*, which can also exist in the soil.

(2) The important tissue nematodes *Wuchereria*, *Onchocerca*, and *Loa* are called the “filarial worms,” because they produce motile embryos called microfilariae in blood and tissue fluids. These organisms are transmitted from person to person by bloodsucking mosquitoes or flies. A fourth species is the guinea worm, *Dracunculus*, whose larvae inhabit tiny crustaceans (copepods) and are ingested in drinking water. The nematodes described above cause disease as a result of the presence of adult worms within the body. In addition, several species cannot mature to adults in human tissue, but their larvae can cause disease.

The most serious of these diseases is visceral larva migrans, caused primarily by the larvae of the dog ascarid, *T. canis*. Cutaneous larva migrans, caused mainly by the larvae of the dog and cat hookworm, *Ancylostoma caninum*, is less serious. A third disease, anisakiasis, is caused by the ingestion of *Anisakis* larvae in raw seafood. In infections caused by certain nematodes that migrate through tissue (e.g., *Strongyloides*, *Trichinella*, *Ascaris*, and the two hookworms *Ancylostoma* and *Necator*), a striking increase in the number of eosinophils (**eosinophilia**) occurs. Eosinophils do not ingest the organisms; rather, they attach to the surface of the parasite via IgE and secrete cytotoxic enzymes contained within their eosinophilic granules. Host defenses against helminths are stimulated by interleukins synthesized by the Th-2 subset of helper T cells (e.g., the production of IgE is increased by interleukin-4, and the number of eosinophils is increased by interleukin-5 [IL-5]). Cysteine proteases produced by the worms to facilitate their migration through tissue are the stimuli for IL-5 production.

ENTEROBIUS

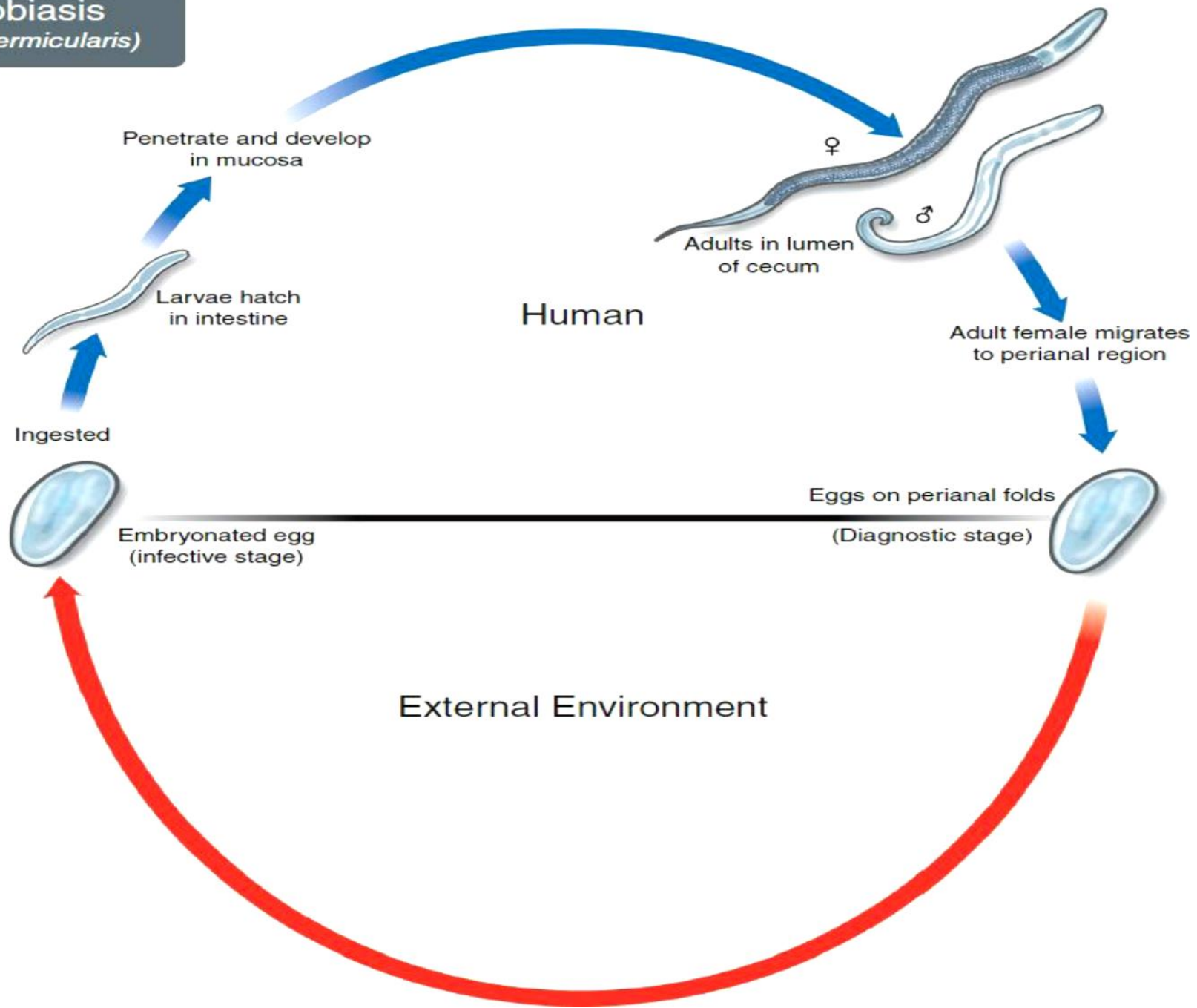
Disease

Enterobius vermicularis causes pinworm infection (enterobiasis).

Important Properties

Infection occurs **only in humans**; there is no animal reservoir or vector. The infection is acquired by ingesting the worm eggs. The eggs hatch in the small intestine, where the larvae differentiate into adults and migrate to the colon. The adult male and female worms live in the colon, where mating occurs. At night, the female migrates from the anus and releases thousands of fertilized eggs on the perianal skin and into the environment. Within 6 hours, the eggs develop into embryonated eggs and become infectious. Reinfection can occur if they are carried to the mouth by fingers after scratching the itching skin.

Enterobiasis (*Enterobius vermicularis*)



Pathogenesis & Clinical Findings

Perianal pruritus is the most prominent symptom. Pruritus is thought to be an allergic reaction to the presence of either the adult female or the eggs. Scratching predisposes to secondary bacterial infection.

Epidemiology

Enterobius is found worldwide and is the **most common** helminth in the United States. Children younger than 12 years of age are the most commonly affected group.

Laboratory Diagnosis

The eggs are recovered from perianal skin by using the **Scotch tape** technique and can be observed microscopically . Unlike those of other intestinal nematodes, these **eggs are not found in the stools**. The small, whitish adult worms can be found in the stools or near the anus of diapered children. No serologic tests are available.

Treatment

Either mebendazole or pyrantel pamoate is effective. They kill the adult worms in the colon but not the eggs, so retreatment in 2 weeks is suggested. Reinfection is very common.

ASCARIS

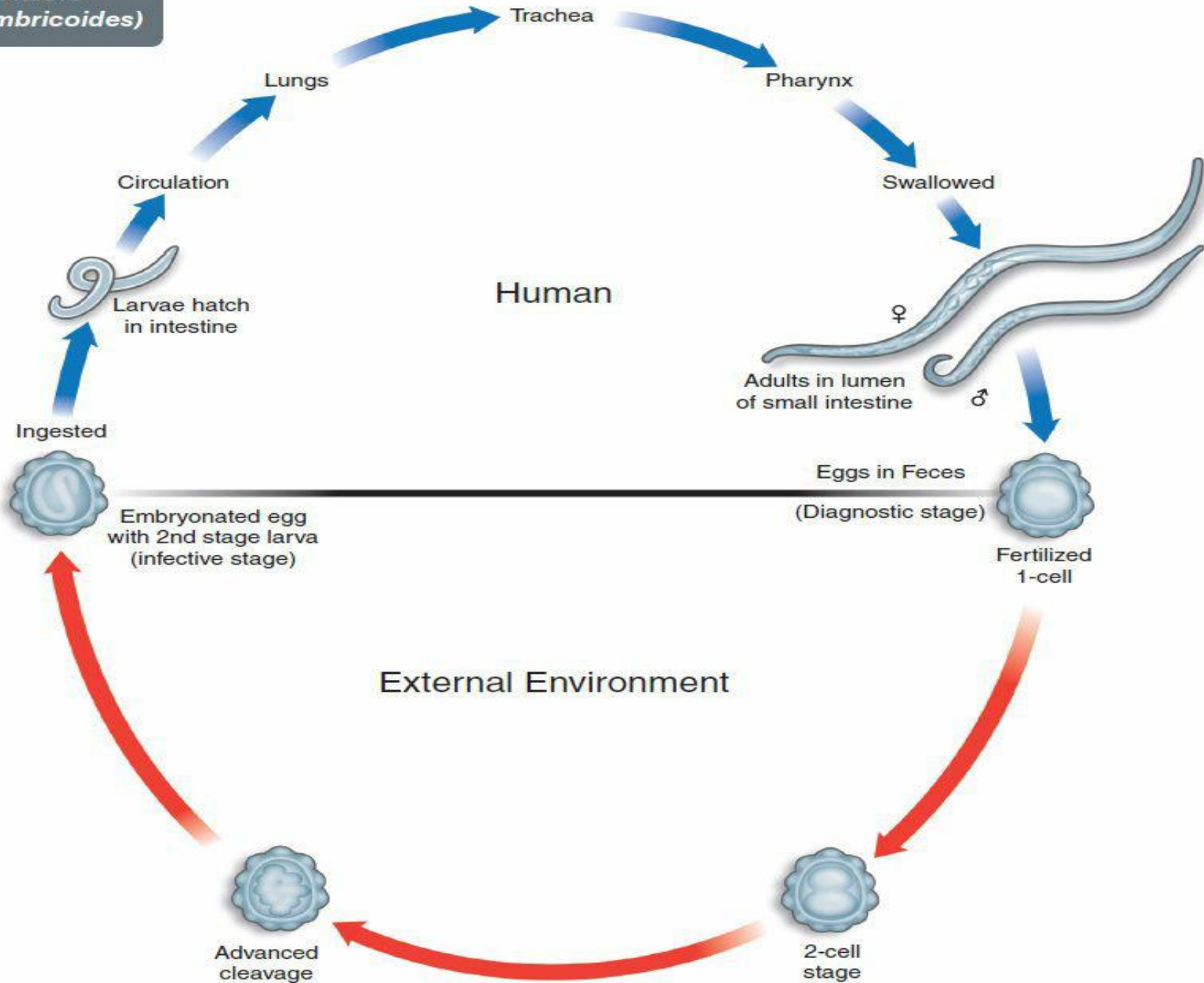
Disease

Ascaris lumbricoides causes ascariasis.

Important Properties

Humans are infected by **ingesting worm eggs** in food or water contaminated with human feces. The eggs hatch in the small intestine, and the larvae migrate through the gut wall into the bloodstream and then to the lungs. They enter the alveoli, pass up the bronchi and trachea, and are swallowed. Within the small intestine, they become adults. They live in the lumen, do not attach to the wall, and derive their sustenance from ingested food.

Ascariasis
(Ascaris lumbricoides)



The adults are the **largest intestinal nematodes**, often growing to 25 cm or more. *A. lumbricoides* is known as the “giant roundworm.” Thousands of eggs are laid daily, are passed in the feces, and differentiate into embryonated eggs in warm, moist soil. Ingestion of the embryonated eggs completes the cycle.

Pathogenesis & Clinical Findings

The major damage occurs during larval migration rather than from the presence of the adult worm in the intestine. The principal sites of tissue reaction are the **lungs**, where inflammation with an **eosinophilic exudate** occurs in response to larval antigens. Because the adults derive their nourishment from ingested food, a heavy worm burden may contribute to malnutrition, especially in children in developing countries. Most infections are asymptomatic. *Ascaris pneumonia* with fever, cough, and eosinophilia can occur with a heavy larval burden. Abdominal pain and even obstruction can result from the presence of adult worms in the intestine.

Epidemiology

Ascaris infection is very common, especially in the tropics; hundreds of millions of people are infected. In the United States, most cases occur in the southern states.

Laboratory Diagnosis

Diagnosis is usually made microscopically by detecting eggs in the stools. The egg is oval with an irregular surface . Occasionally, the patient sees adult worms in the stools.

Treatment

Both mebendazole and pyrantel pamoate are effective.

ANCYLOSTOMA & NECATOR

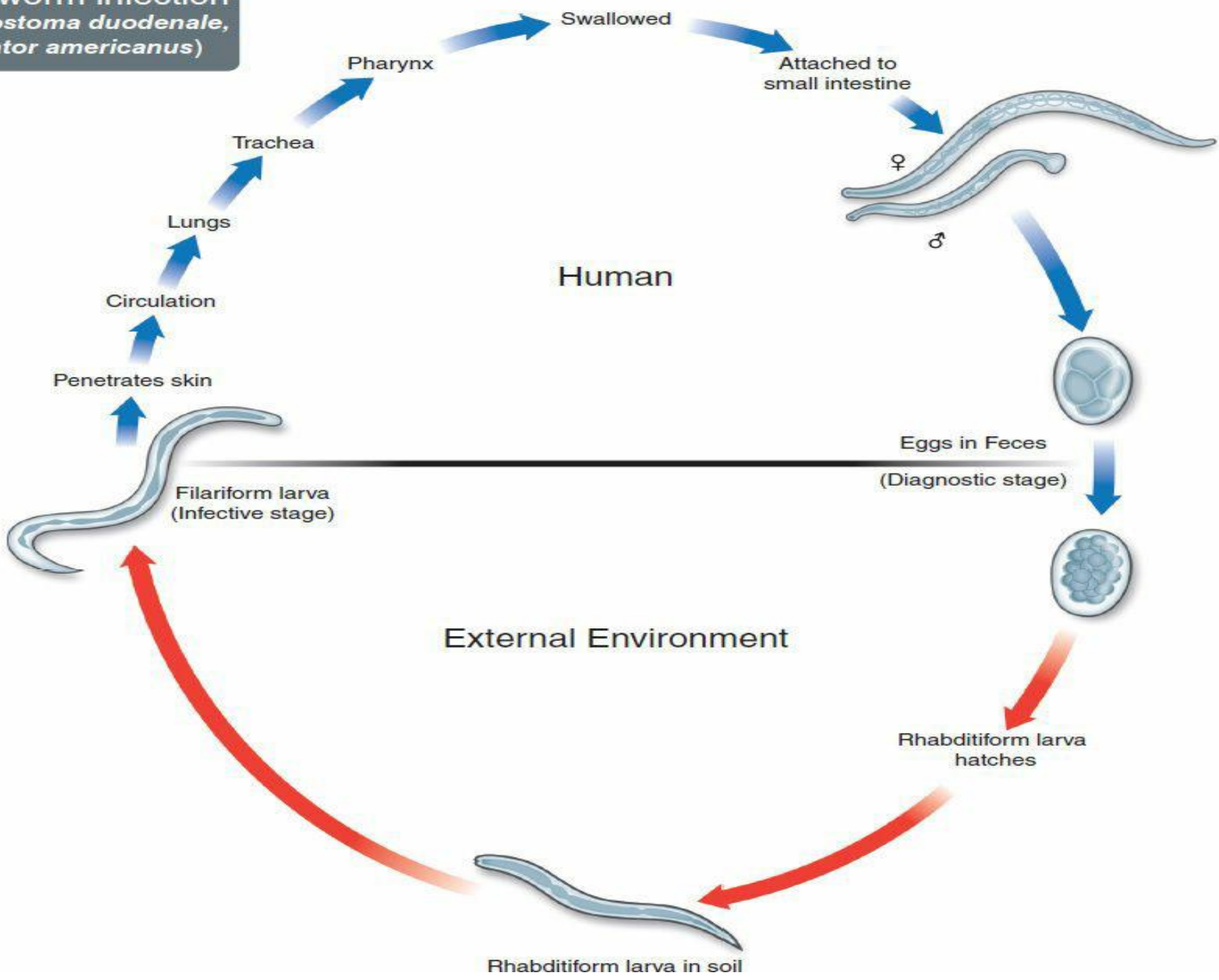
Disease

Ancylostoma duodenale (Old World hookworm) and *Necator americanus* (New World hookworm) cause hookworm infection.

Important Properties

Humans are infected when **filariform larvae in moist soil penetrate the skin**, usually of the feet or legs. They are carried by the blood to the lungs, migrate into the alveoli and up the bronchi and trachea, and then are swallowed. They develop into adults in the small intestine, attaching to the wall with either cutting plates (*Necator*) or teeth (*Ancylostoma*). They feed on blood from the capillaries of the intestinal villi. Thousands of eggs per day are passed in the feces. Eggs develop first into noninfectious, feeding (rhabditiform) larvae and then into third-stage, infectious, nonfeeding (filariform) larvae, which penetrate the skin to complete the cycle.

Hookworm infection
(*Ancylostoma duodenale*,
Necator americanus)



Pathogenesis & Clinical Findings

The major damage is due to the **loss of blood** at the site of attachment in the small intestine. Up to 0.1 to 0.3 mL per worm can be lost per day. Blood is consumed by the worm and oozes from the site in response to an anticoagulant made by the worm. Weakness and pallor accompany the microcytic anemia caused by blood loss. These symptoms occur in patients whose nutrition cannot compensate for the blood loss. “Ground itch,” a pruritic papule or vesicle, can occur at the site of entry of the larvae into the skin. Pneumonia with eosinophilia can be seen during larval migration through the lungs.

Epidemiology

Hookworm is found worldwide, especially in tropical areas.

Laboratory Diagnosis

Diagnosis is made microscopically by observing the eggs in the stools. Occult blood in the stools is frequent. Eosinophilia is typical.

Treatment

Both mebendazole and pyrantel pamoate are effective.