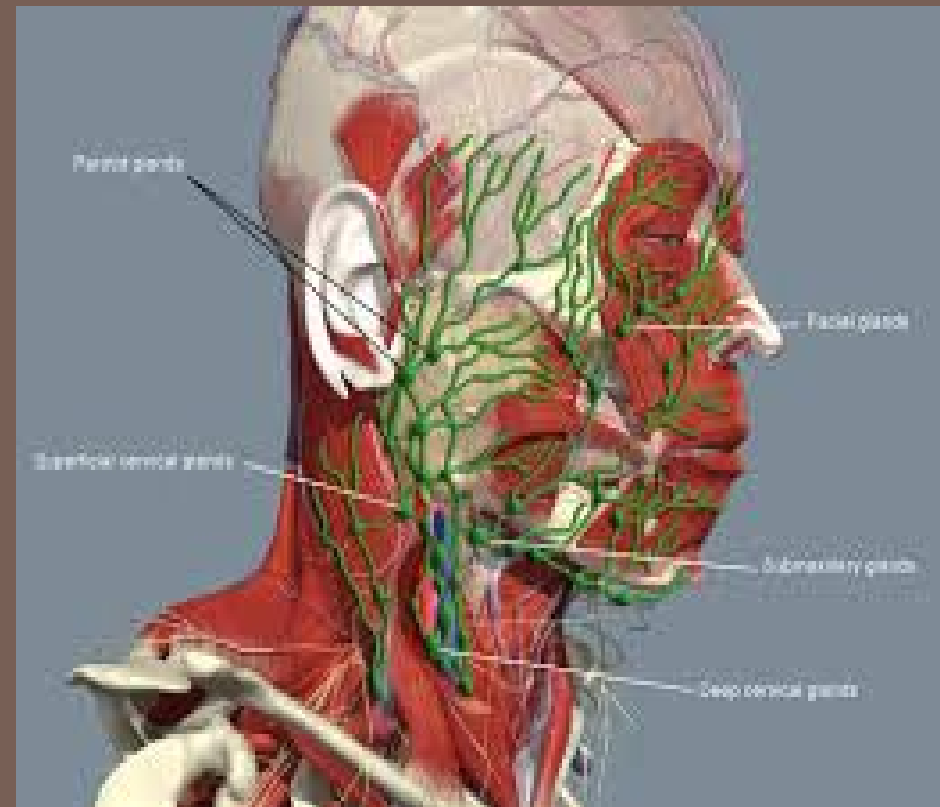


# LYMPHATIC SYSTEM



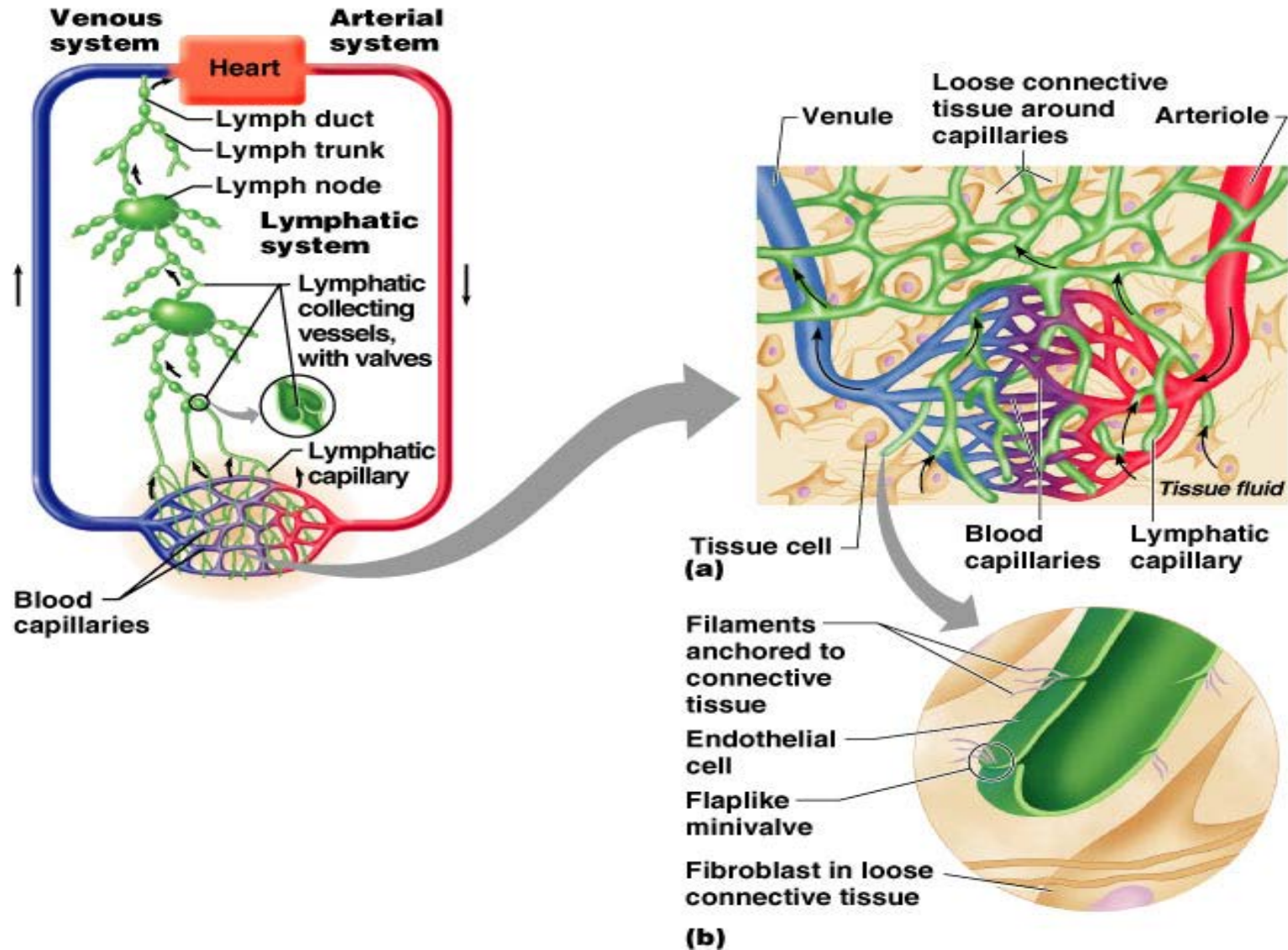
# LYMPH

---

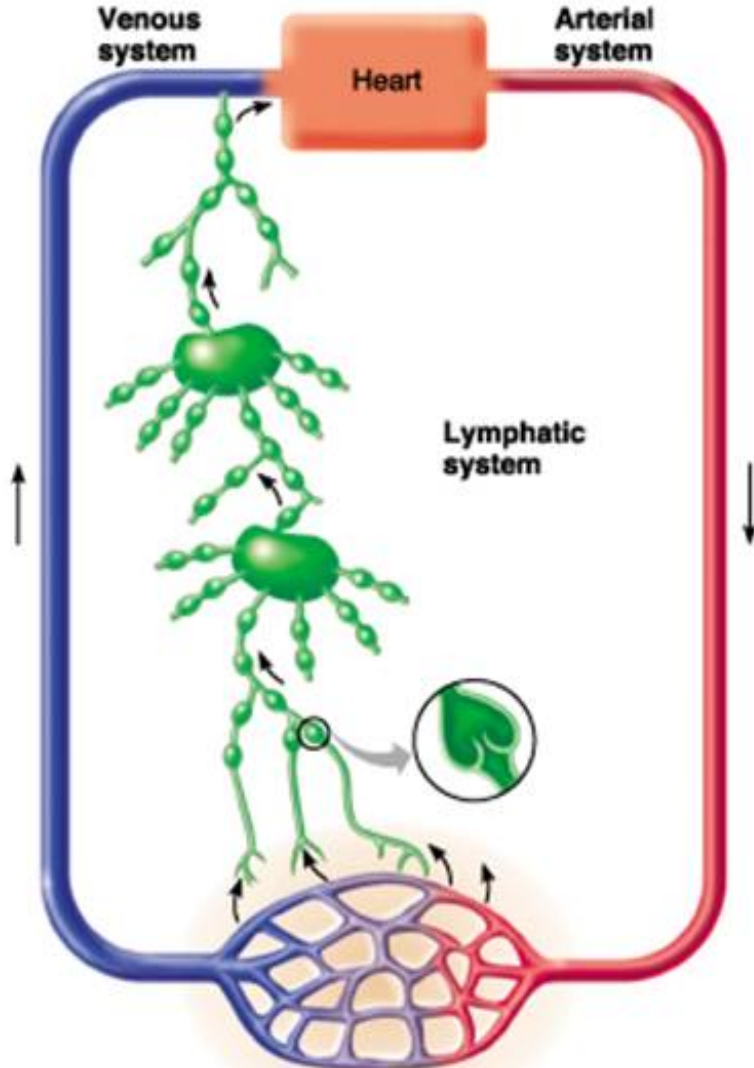
- **What is lymph?**

**Tissue fluid (interstitial fluid) that enters the lymphatic vessels**

# FORMATION AND TRANSPORT OF TISSUE FLUID



# LYMPHATIC SYSTEM



*Essentially a drainage system accessory to venous system*

*larger particles that escape into tissue fluid can only be removed via lymphatic system*

# Functions of the Lymphatic System

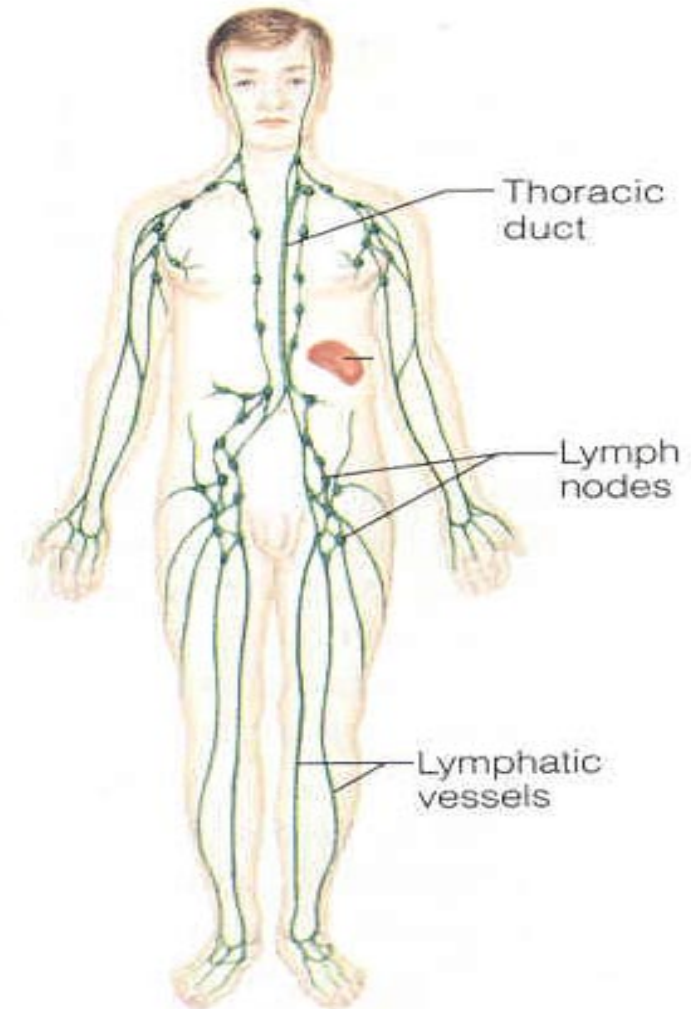
24-

- **Reabsorbs excess interstitial fluid:**
  - returns it to the venous circulation
  - maintain blood volume levels
  - prevent interstitial fluid levels from rising out of control.
  
- **Transport dietary lipids:**
  - transported through **lacteals**
  - drain into larger lymphatic vessels
  - eventually into the bloodstream.
  
- **lymphocyte development, and the immune response .**

# Components of the Lymphatic System

24-

- **Lymph**
- **Lymphatic Vessels**
  - **Lymphatic Capillaries**
  - **Lymphatic Vessels**
  - **Lymphatic Trunks**
  - **Lymphatic Ducts**
- **Lymphatic Organs**
  - **Thymus**
  - **Lymph Nodes**
  - **Spleen**
  - **Tonsils**
- **Lymphatic cells**



Lymphatic system

# Lymph Vessels

- Lymphatic **capillaries**—
- Lymphatic **collecting vessels**
- Lymphatic **trunks** —
- Lymphatic **ducts** —

**Lymphatic capillary**



**Lymphatic vessel**



**Lymph node**



**Lymphatic vessel**



**Lymphatic trunk**



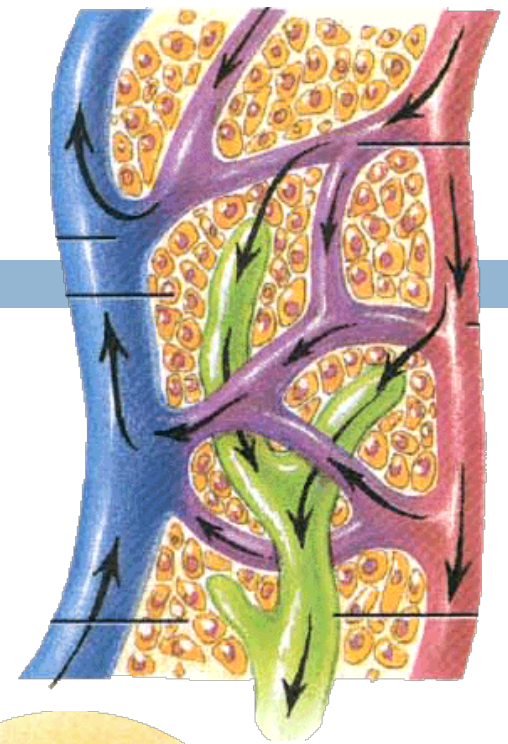
**Collecting duct**



**Subclavian vein**

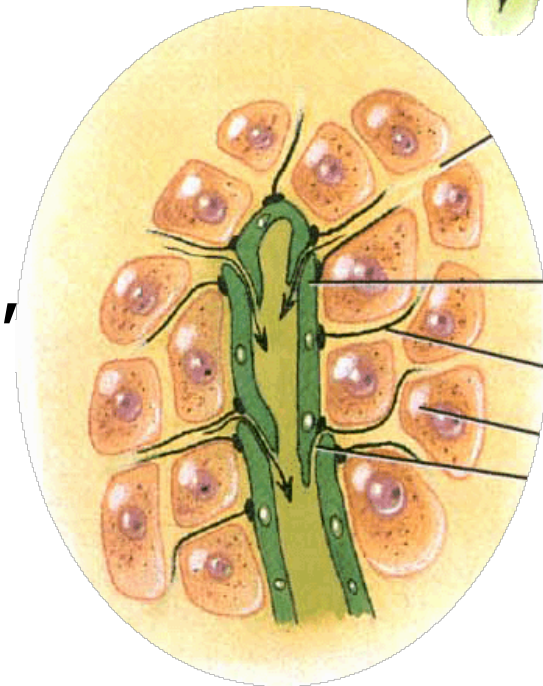


# Lymphatic Capillaries



## Features of structure :

- Blind end
- Single layer of overlapping endothelial cells
- More permeable than that of blood capillary
- Absent from avascular structures, brain, spinal cord splenic pulp and bone marrow



# Lymphatic Capillaries – Lacteals

24-

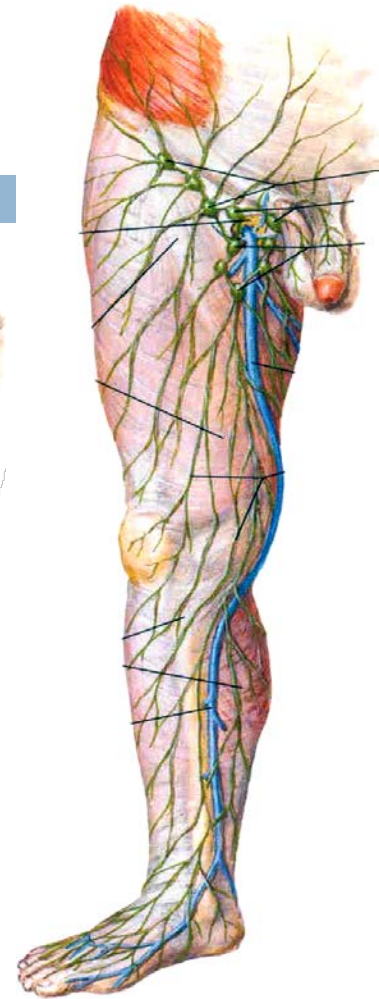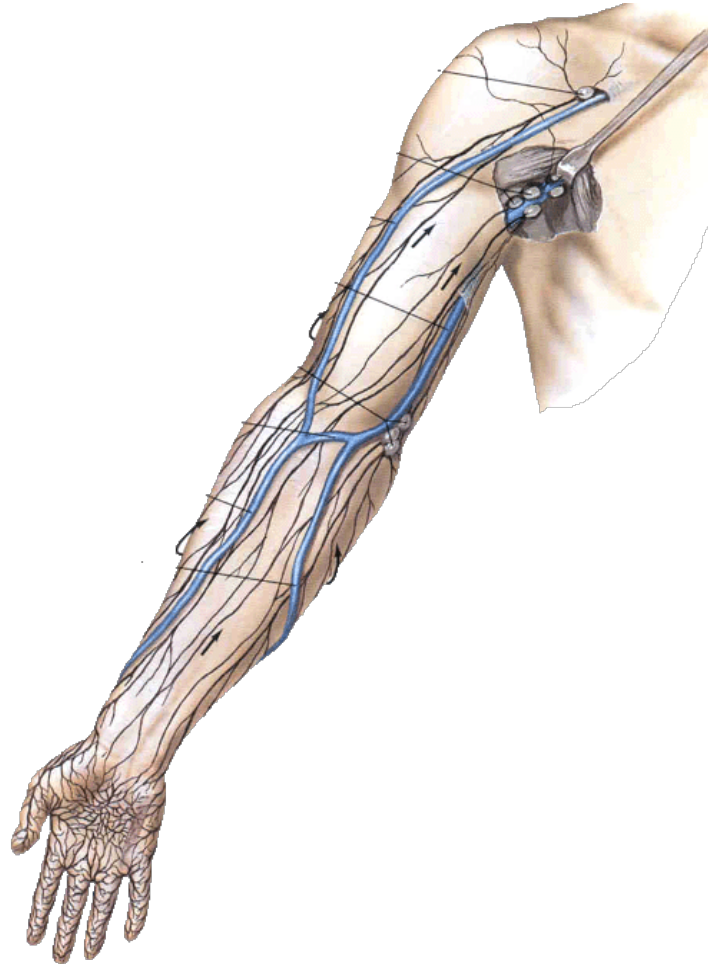- The **small intestine** contains special types of lymphatic capillaries called lacteals .
- **Lacteals** pick up not only interstitial fluid, but also dietary lipids and lipid-soluble vitamins .
- The lymph of this area has a milky color due to the lipid and is also called **chyle**.

# Lymphatic Vessels

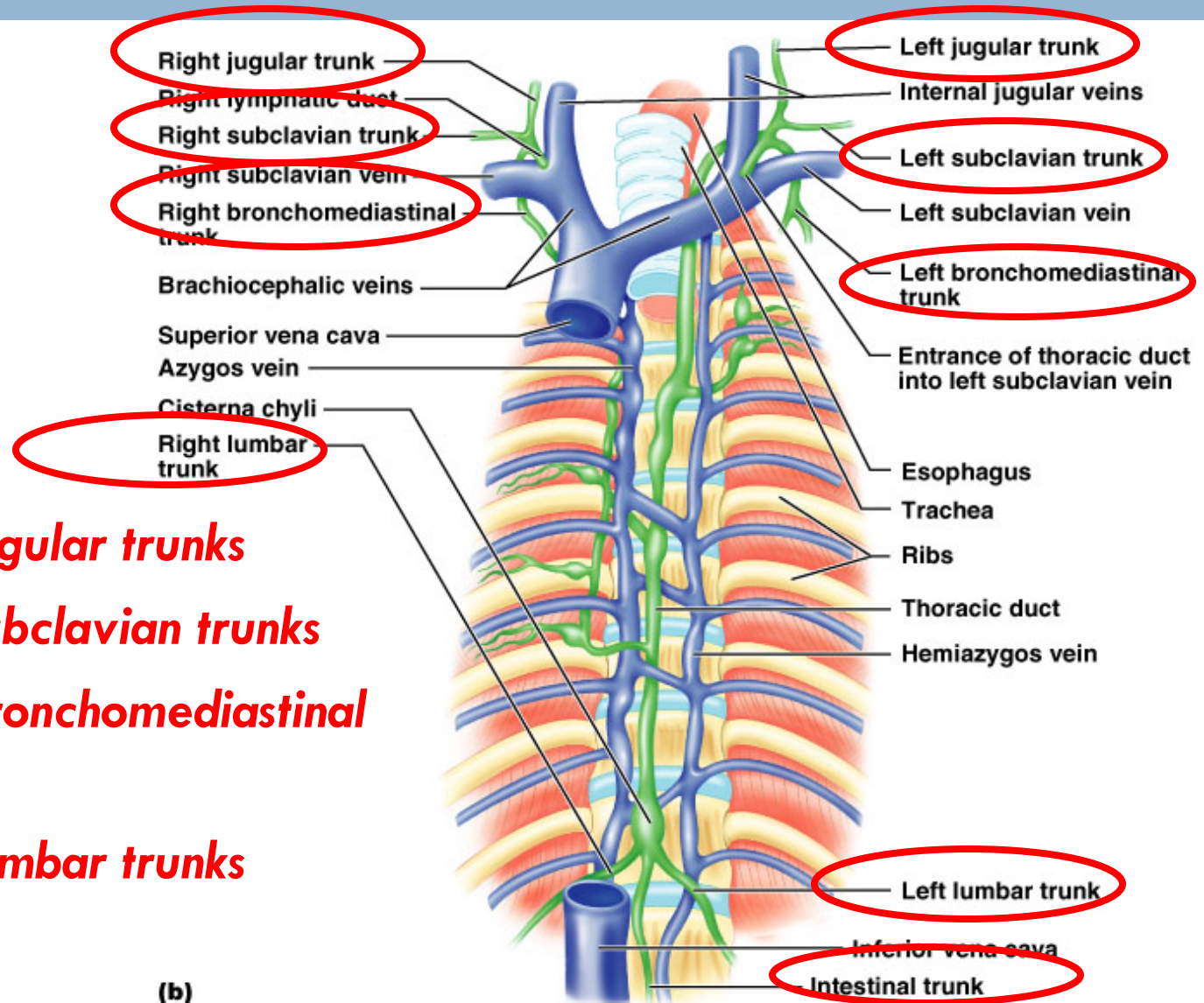
24-

## Features of structure

- ❑ Three layered wall but thinner than vein
- ❑ More numerous valves than in vein
- ❑ Interposed by lymph nodes at intervals
- ❑ Arranged in superficial and deep sets



# LYMPH TRUNKS



(b)

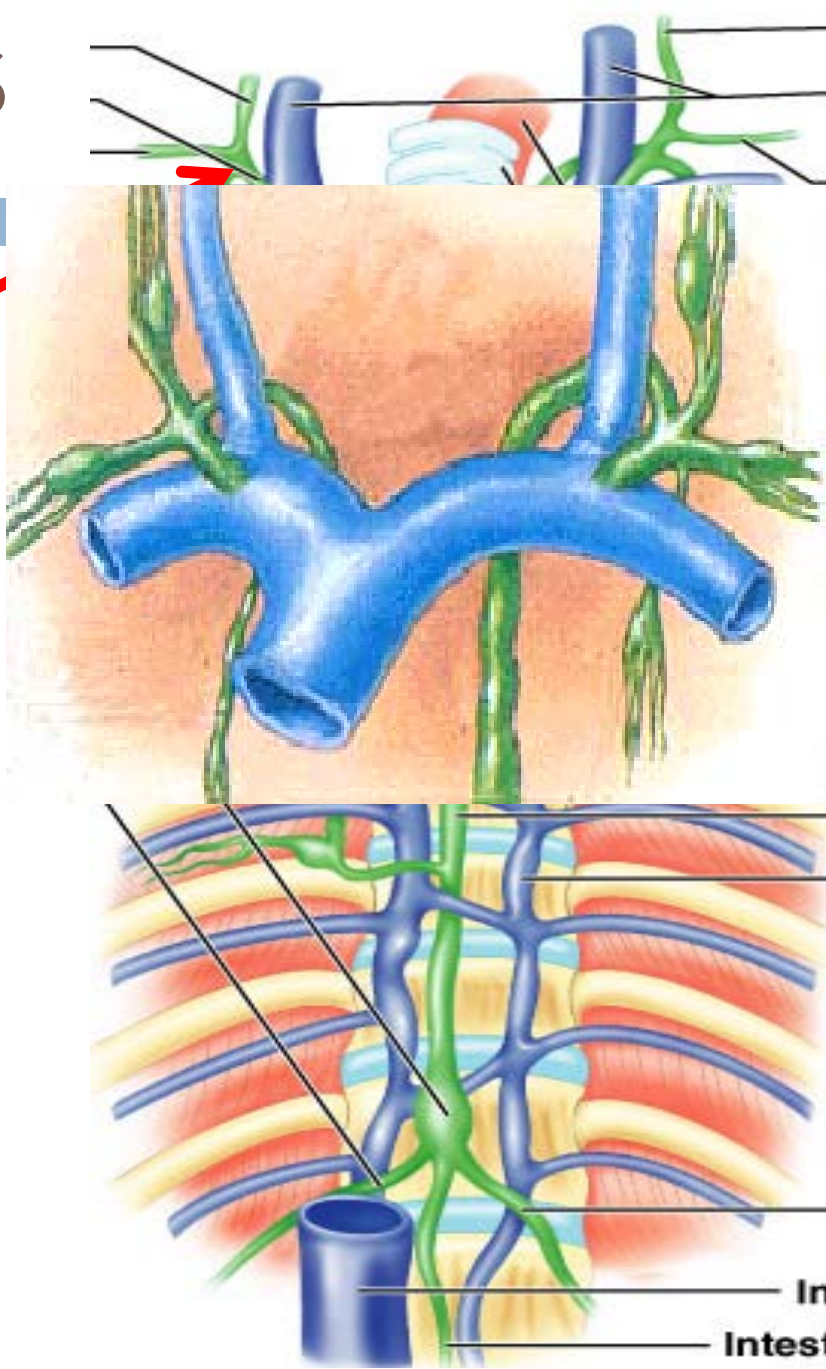
- right and left **jugular trunks**
- right and left **subclavian trunks**
- right and left **bronchomediastinal trunks**
- right and left **lumbar trunks**
- intestinal trunk**

# LYMPHATIC DUCTS

24-

## Right lymphatic duct

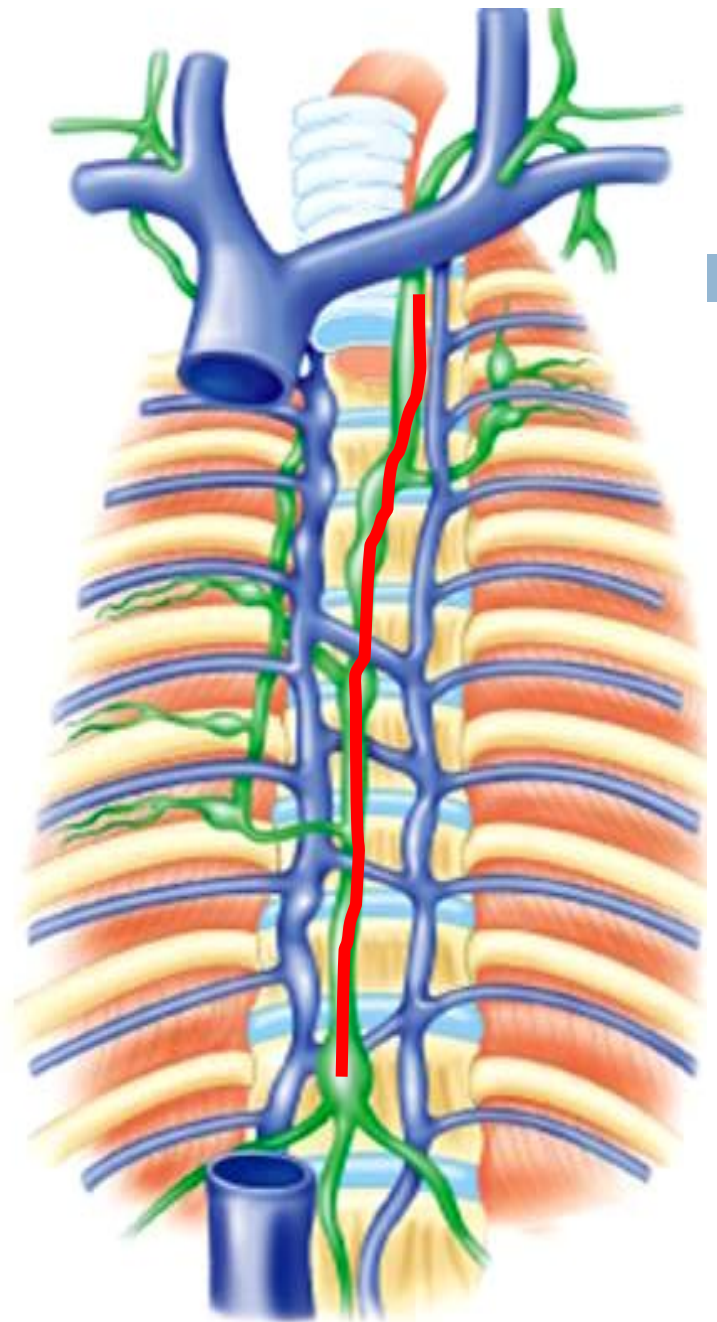
- Formed by union of **right jugular, subclavian, and bronchomediastinal trunks**
- Ends by entering the **right venous angle**



# LYMPHATIC DUCTS

## □ Thoracic duct

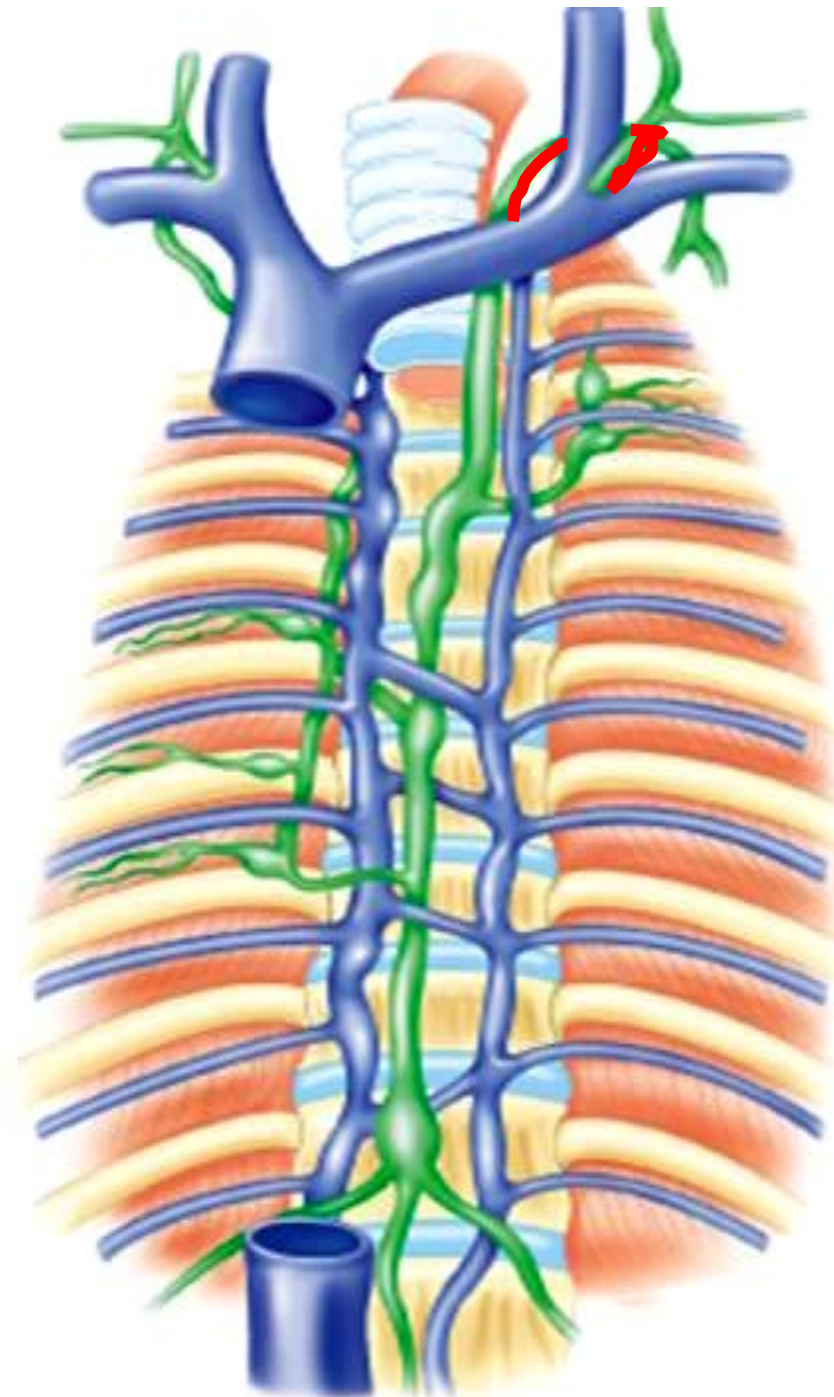
- Begins in front of L<sup>1</sup> as a dilated sac, the **cisterna chyli**
- formed by left and right lumbar trunks and intestinal trunk
- Enter thoracic cavity & ascends
- Travels upward, veering to the left at the level of T<sub>8</sub>



# THORACIC DUCT.....

۱۵

- **At the root of the neck, it turns laterally**
- **arches forwards and descends to enter the left venous angle**
- **before termination, it receives the left jugular, Subclavian and broncho-mediastinal trunk**

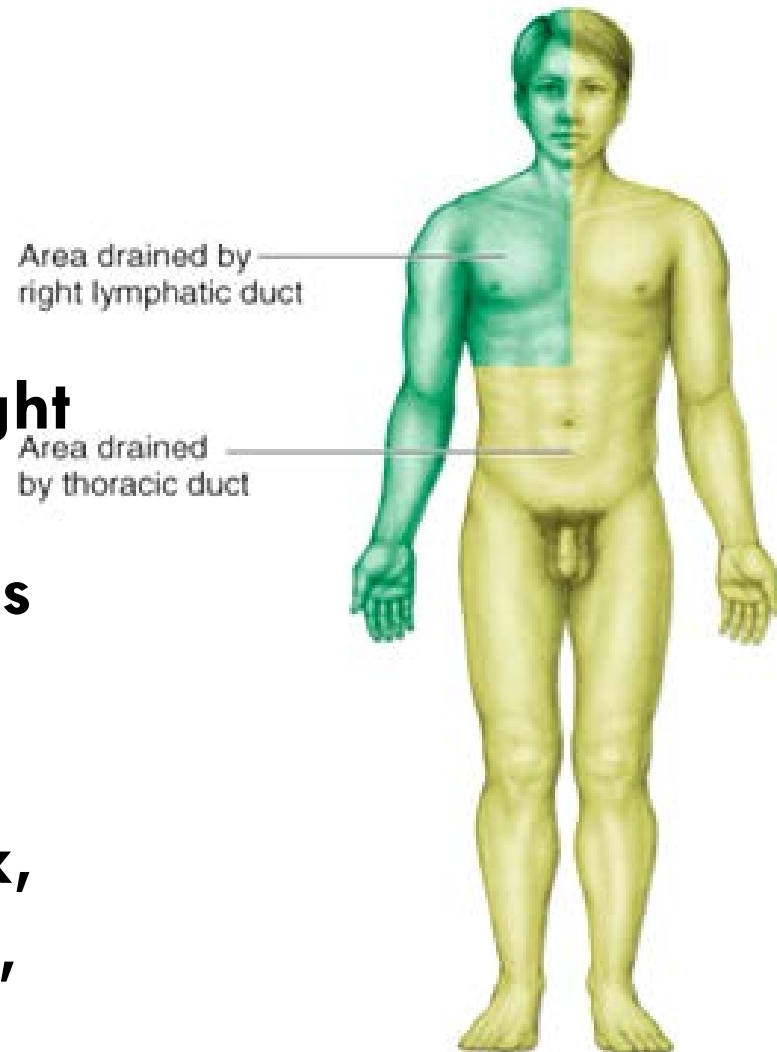


# DRAINAGE PATTERN

## **RIGHT LYMPHATIC DUCT -**

Receives lymph from right half of head, neck, thorax and right upper limb, right lung, right side of heart, right surface of liver

**THORACIC DUCT -** Drains lymph from lower limbs, pelvic cavity, abdominal cavity, left side of thorax, and left side of the head, neck and left upper limb



(b) Lymph drainage pattern



# Lymphatic Cells

24-

- Also called **lymphoid cells** .
- Located in both the lymphatic system and the cardiovascular system .
- Work together to elicit an **immune response** .
- Types of lymphatic cells are :
  - **macrophages**
  - **epithelial cells**
  - **dendritic cells**
  - **lymphocytes**

# LYMPHATIC ORGANS

## Primary organs

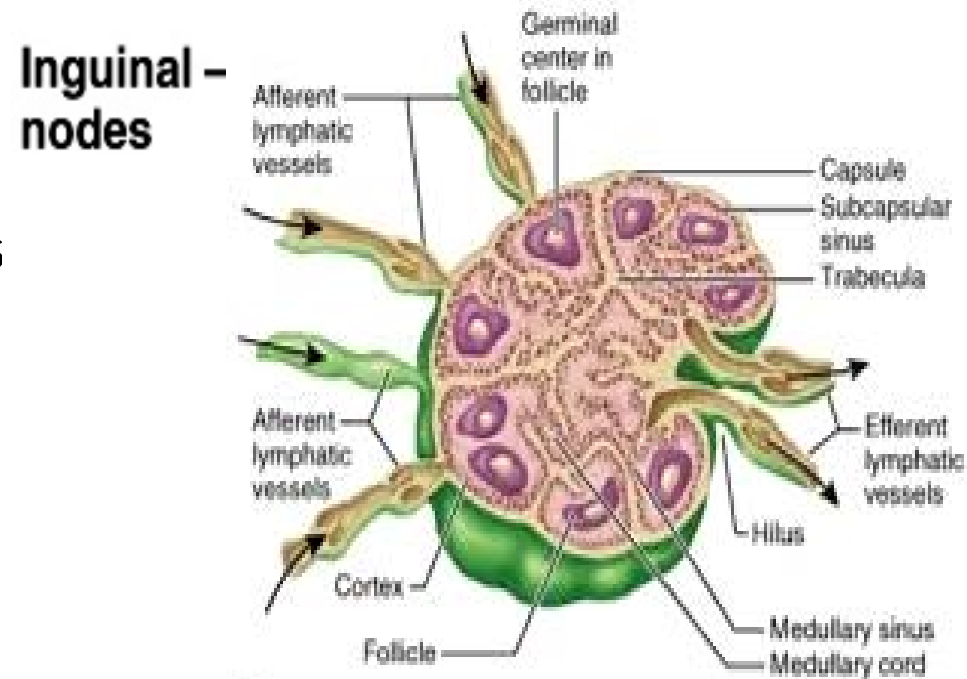
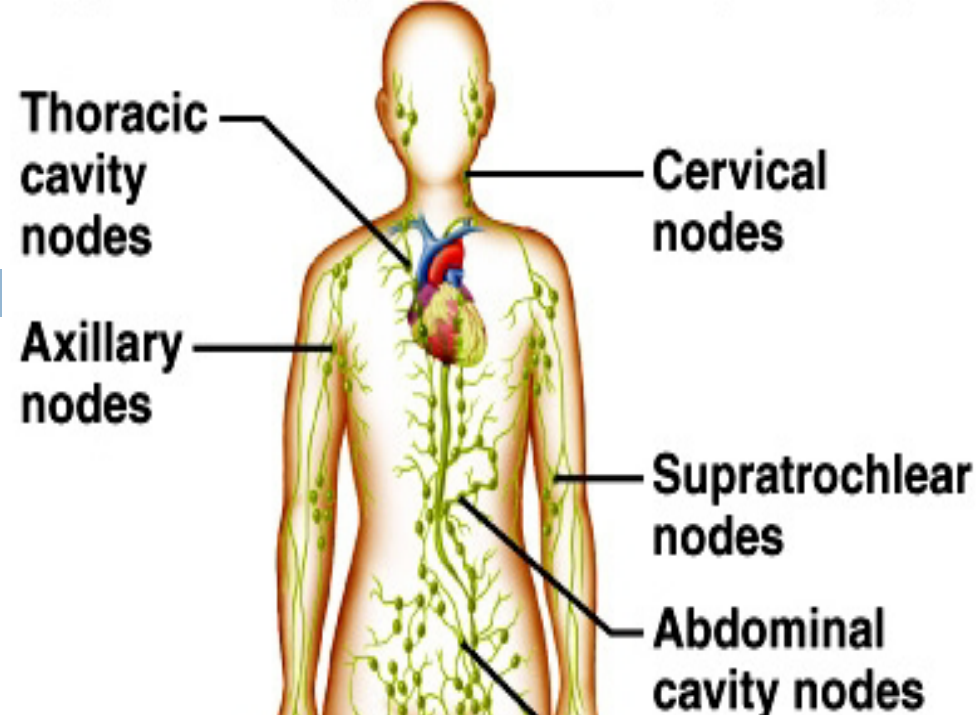
- ▣ Red bone marrow
- ▣ Thymus gland

## Secondary organs

- ▣ Lymph nodes
- ▣ Lymph nodules
- ▣ Spleen

# Lymph Nodes

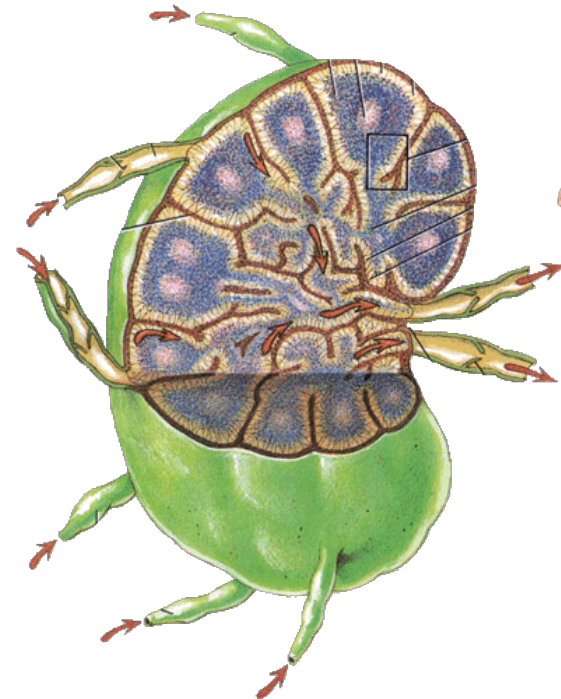
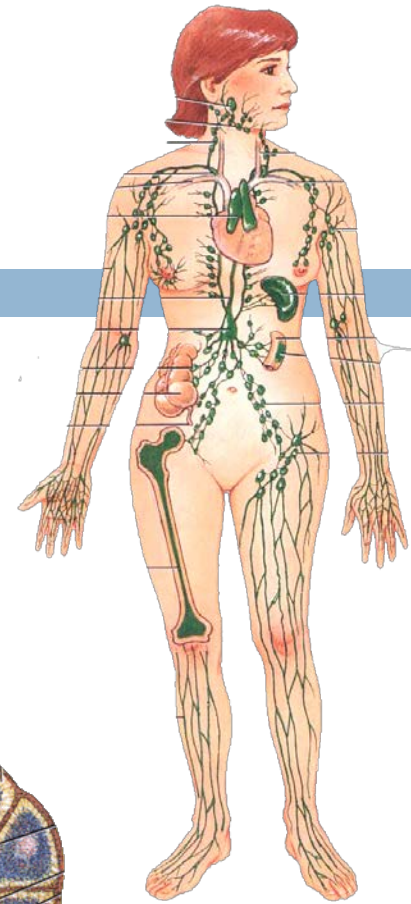
- 24-  Small, round or oval
- located along the **pathways** of lymph vessels .
- length from 1 - 25 millimeters
- Typically found in clusters
- receive lymph from many body regions .
- Lymph nodes are also found individually



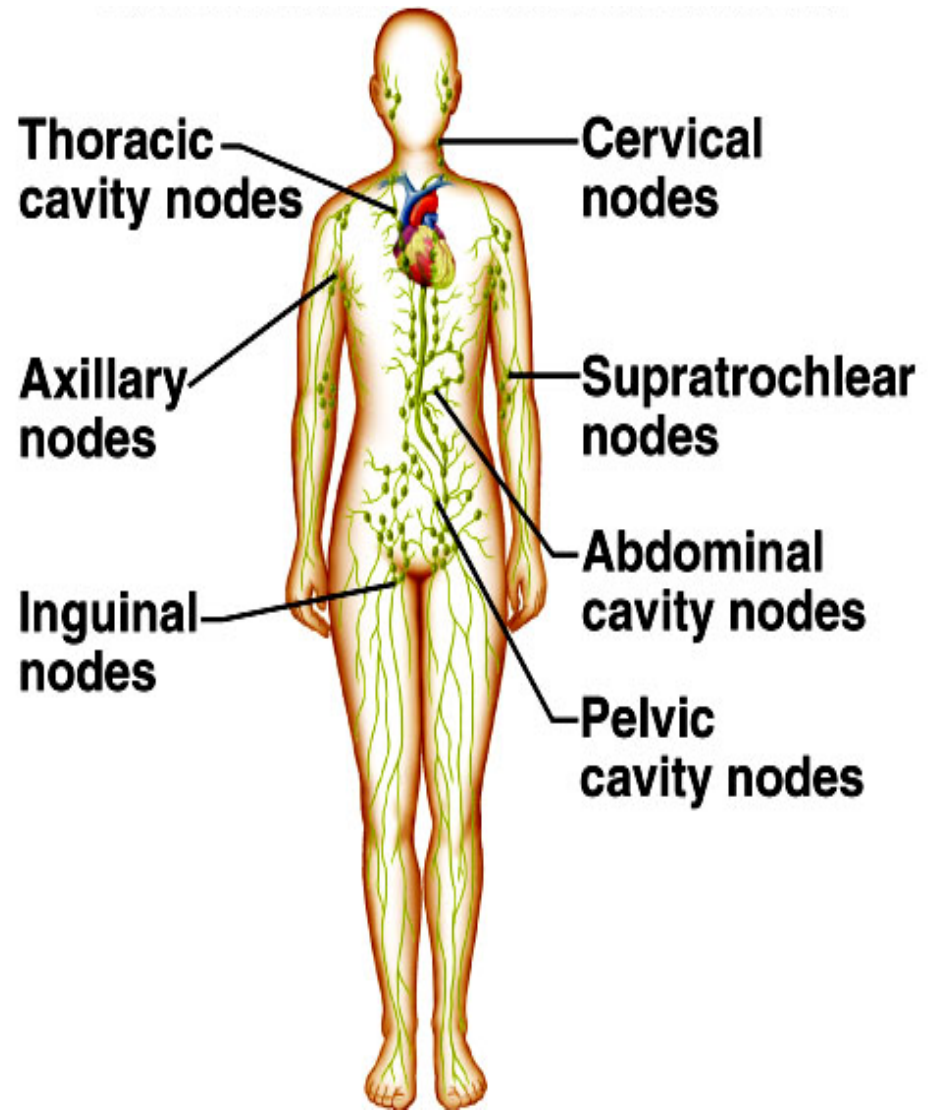
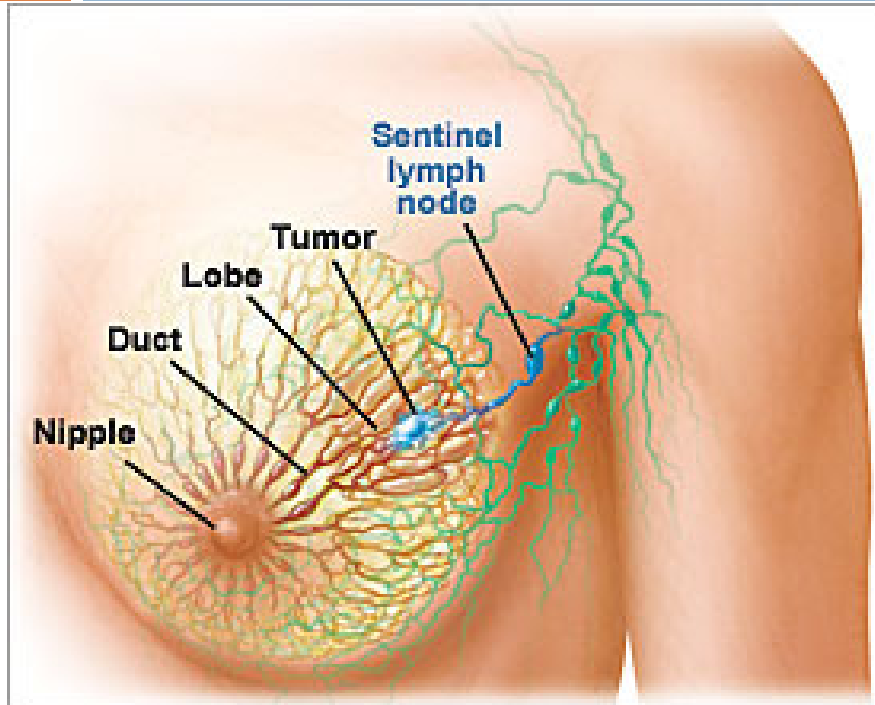
# Lymph node

## Features

- ❑ Bean-shaped bodies
- ❑ With **afferent vessels** (entering at the periphery) and **efferent lymph vessels** (emerging at the hilus)
- ❑ Arranged in groups, along the blood vessels or the flexural side of the joint
- ❑ Divided into **superficial and deep** groups



# Regional Lymph drainage

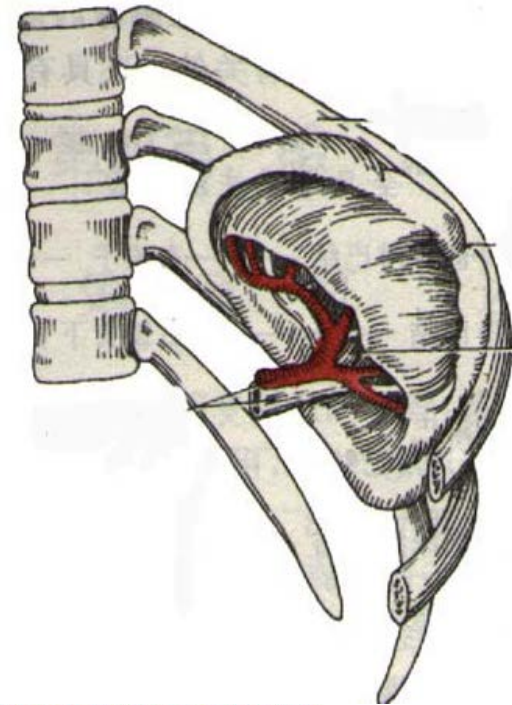
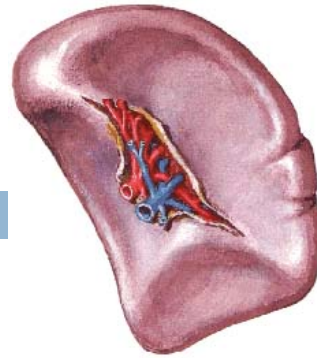


Regional Lymph Node is the lymph node where the lymph of the organ or part of the body drainage to firstly

**Sentinel Lymph Node**(in clinic)

# Spleen

۲۲



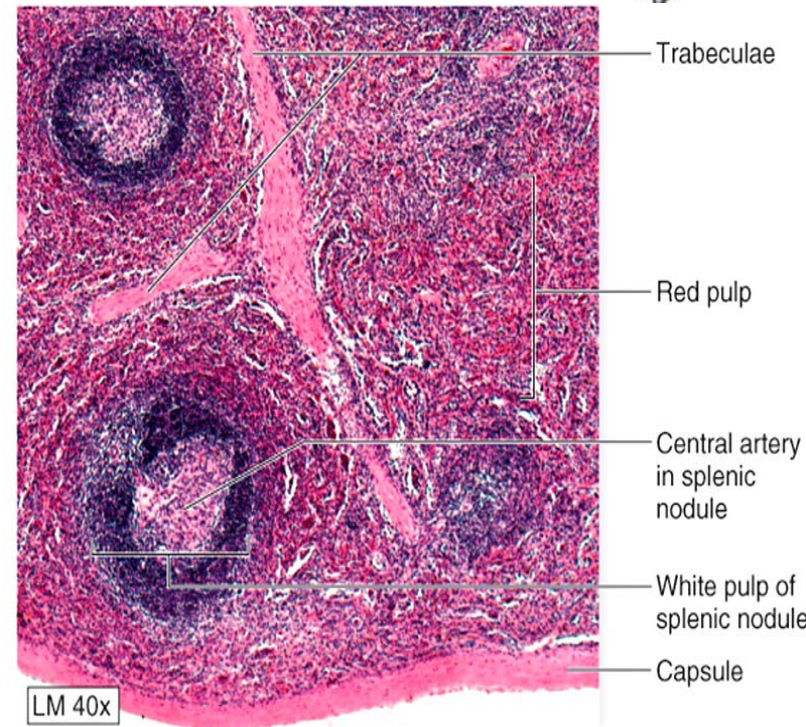
## Location

- Left epigastric region
- between 9<sup>th</sup>-11<sup>th</sup> rib
- in line of 10<sup>th</sup> rib

□ **Largest** lymphatic organ in the body .

□ Can vary considerably in size and weight

## Function

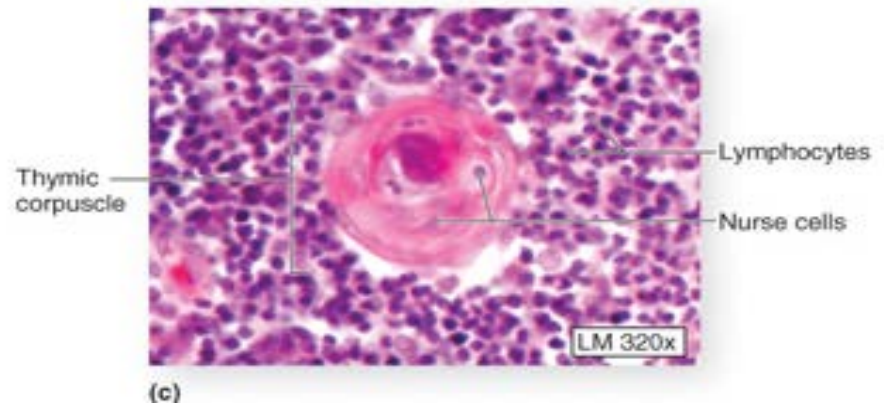
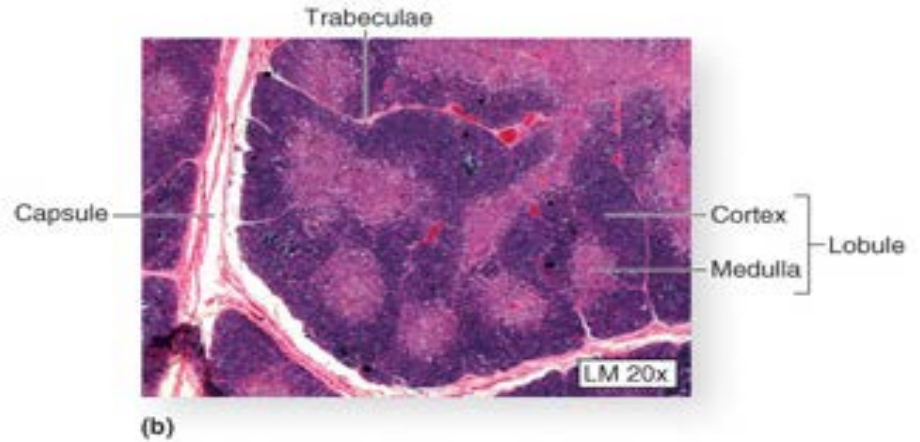
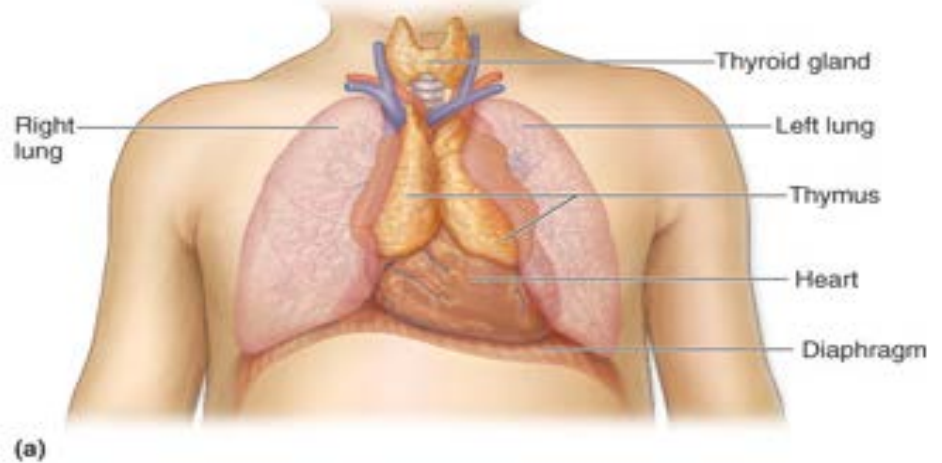


# THYMUS

۲۳

## Features

- ❑ Consists of two elongated lobes
- ❑ Is a large organ in the fetus
- ❑ Occupies the thoracic cavity behind the sternum
- ❑ Secrete lymphopoietin



# Lymphatic Nodules

24-

- **Oval clusters of lymphatic cells with some extracellular matrix that are not surrounded by a connective tissue capsule.**
  
- Filter and attack antigens .
  
- In some areas of the body, many lymphatic nodules group together to form larger structures.
  - mucosa-associated lymphatic tissue (MALT) or tonsils
  - very prominent in the mucosa of the small intestine, primarily in the ileum
    - **Peyer patches**
  - also present in the appendix



# MALT

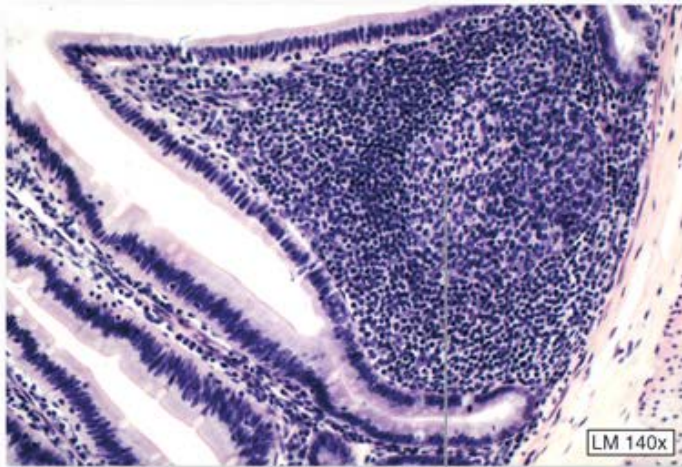
- MALT – mucosa-associated lymphatic tissue:
  - Peyer's patches, tonsils, and the appendix (digestive tract)
  - Lymphoid nodules in the walls of the bronchi (respiratory tract)
- MALT protects the digestive and respiratory systems from foreign matter

# Tonsils

24-

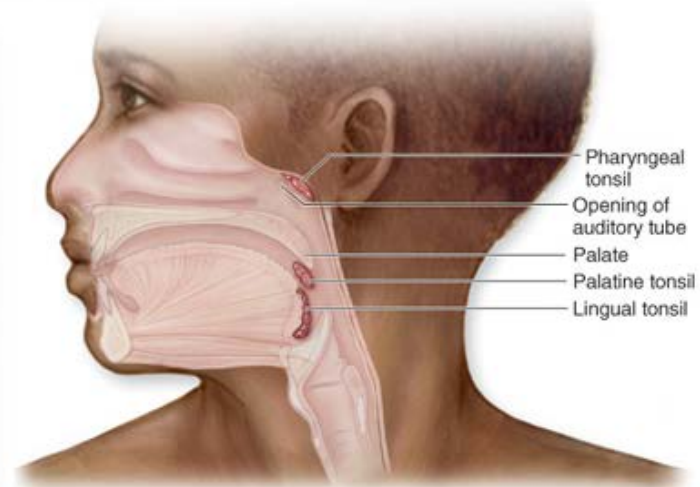
- **clusters of lymphatic cells and extracellular matrix not completely surrounded by a connective tissue capsule.**
- **Consist of multiple germinal centers and crypts**
- **Several groups of tonsils form a protective ring around the pharynx .**
  - **pharyngeal tonsils (or adenoids) in nasopharynx**
  - **palatine tonsils in oral cavity**
  - **lingual tonsils along posterior one-third of the tongue**

# MALT (Mucosa Associated Lymphoid Tissue)

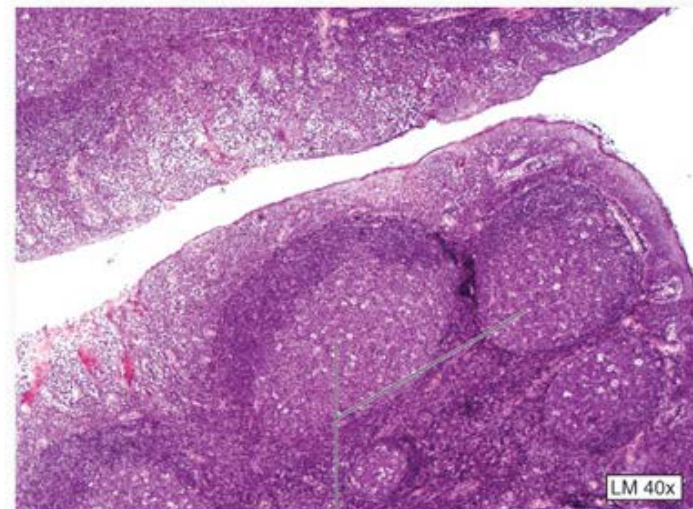


Simple columnar epithelium of small intestine      MALT (Peyer patches)

(a)



(b)

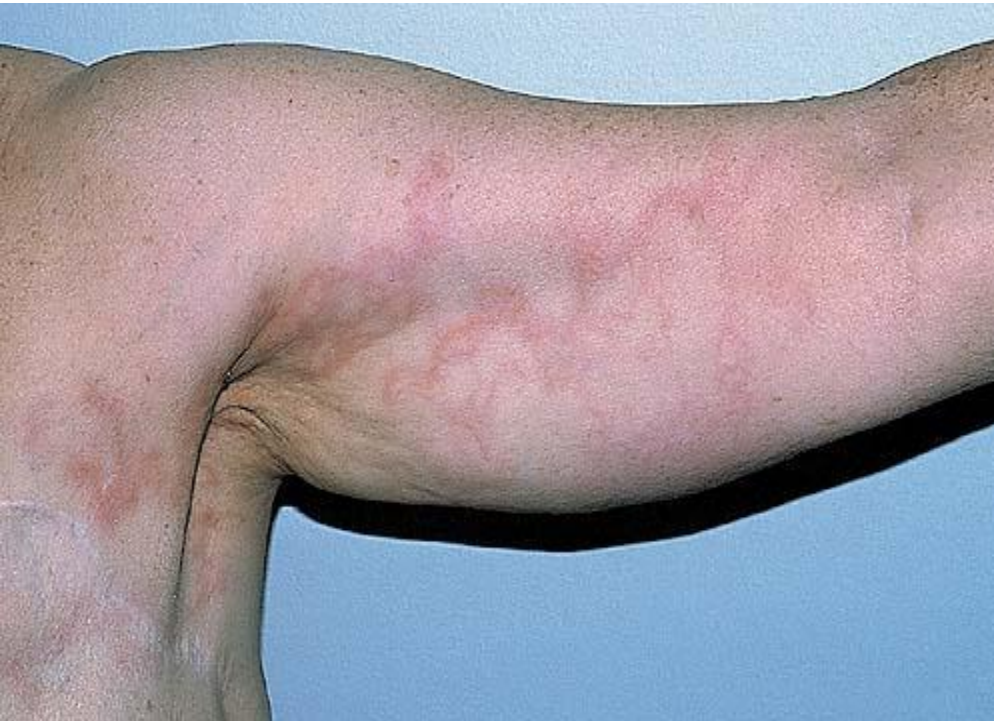

Lymphatic nodules

# APPLIED ANATOMY



# LYMPHANGITIS

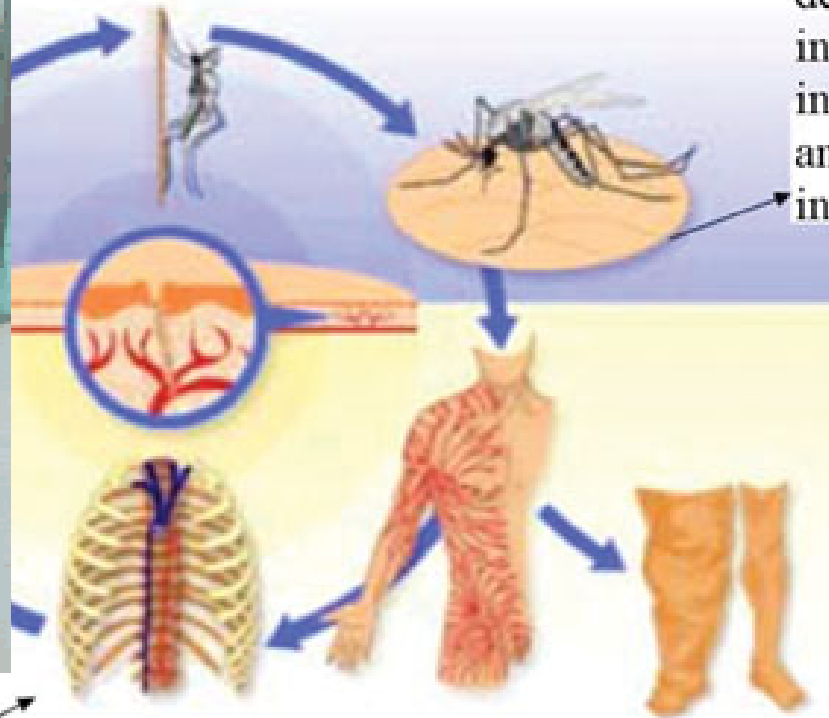


**Inflammation of the lymph vessels**

**Commonest cause bacteria called streptococcus pyogenes (most common).**

- **Lymph vessels appear as red streaks through the skin**

# FILARIASIS

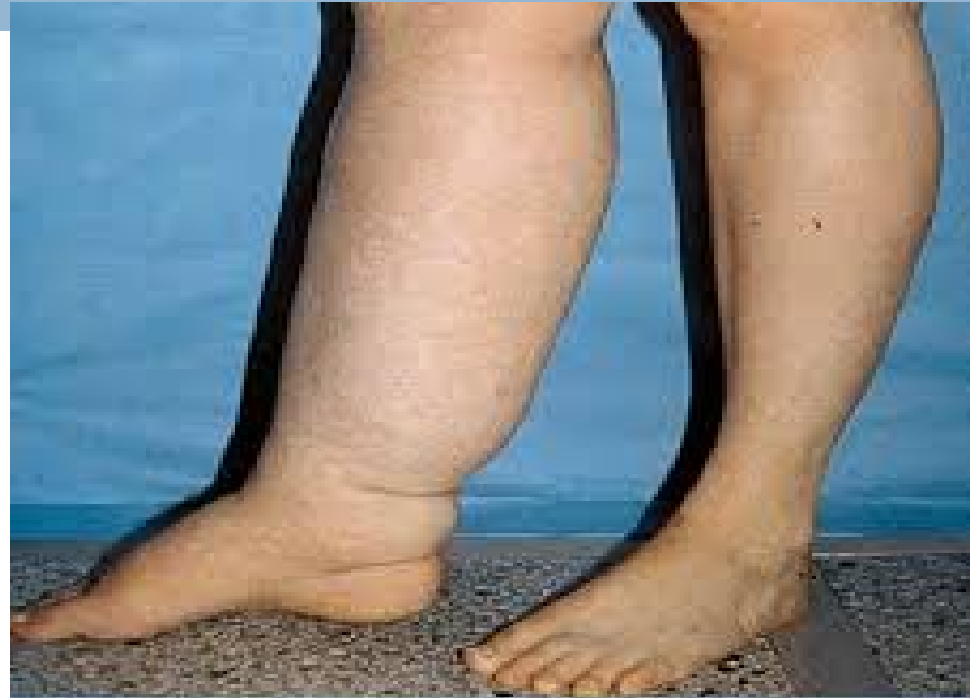

(b) Microfilaria develop into infective larvae in the mosquito and are injected into a new host

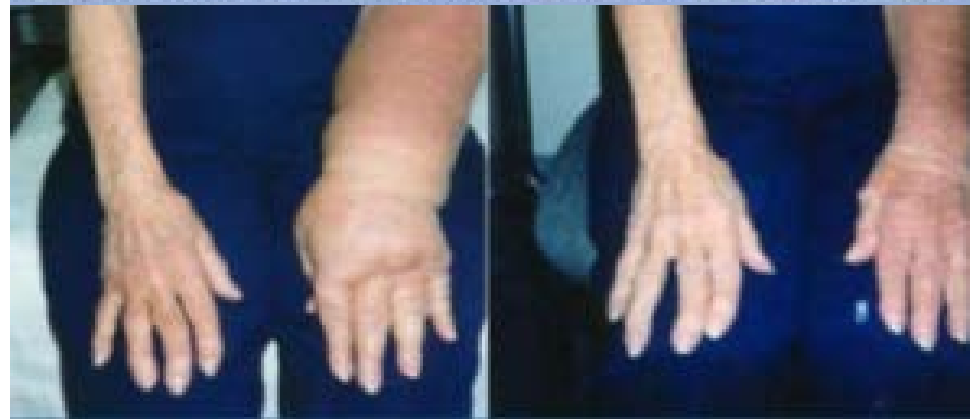(c) Larvae mature into adult worms and spread through the lymphatic vessels, where they mate and lay eggs

# LYMPHEDEMA

- Occurs due to **accumulation of lymphatic fluid** in the interstitial tissue
- Sometimes can be appreciated after wearing tight clothing or jewellery on affected limb

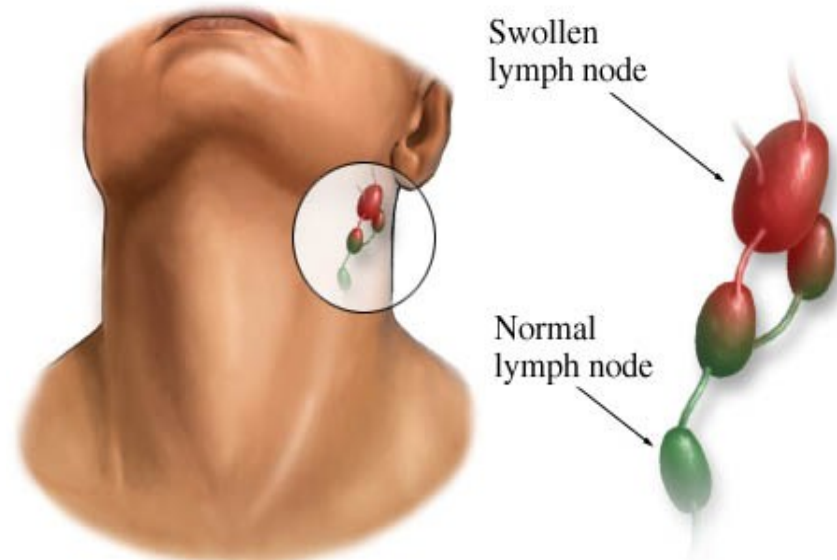
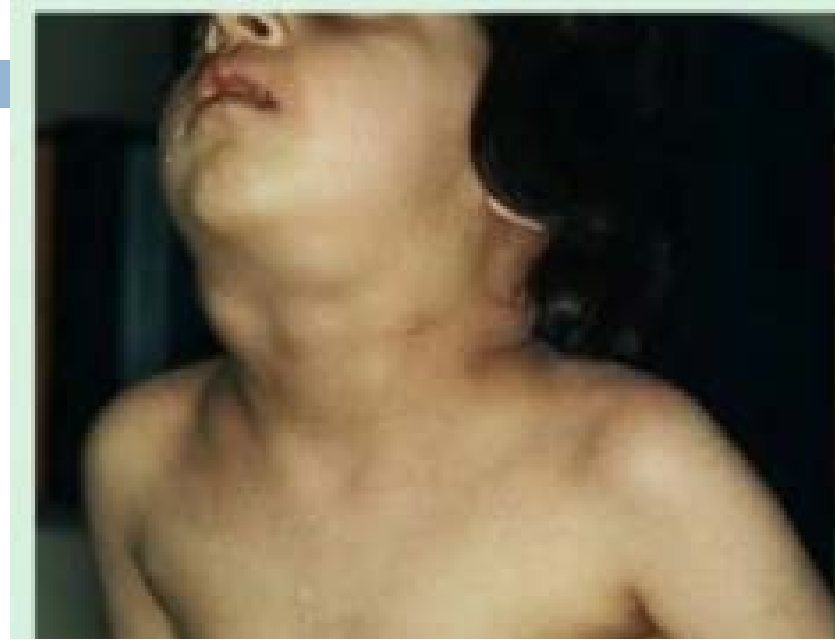

© Mayo Foundation for Medical Education and Research. All rights reserved.



# LYMPHADENOPATHY

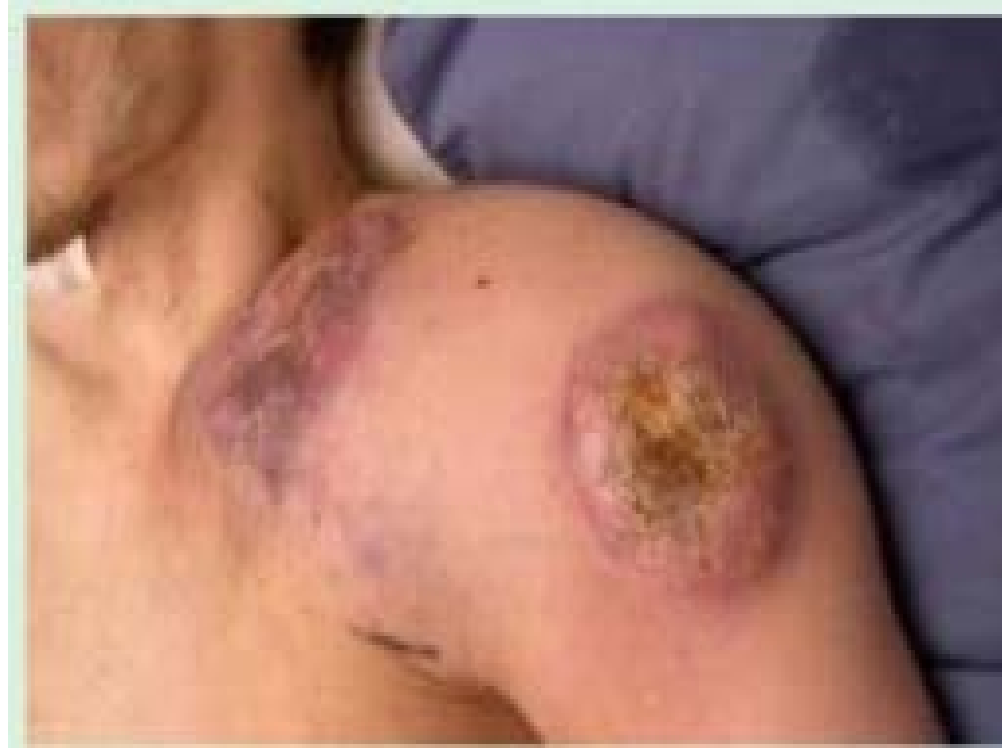- Means a **disease of the lymph nodes**
- Lymph nodes become **swollen/ enlarged** and may be **painful to touch**





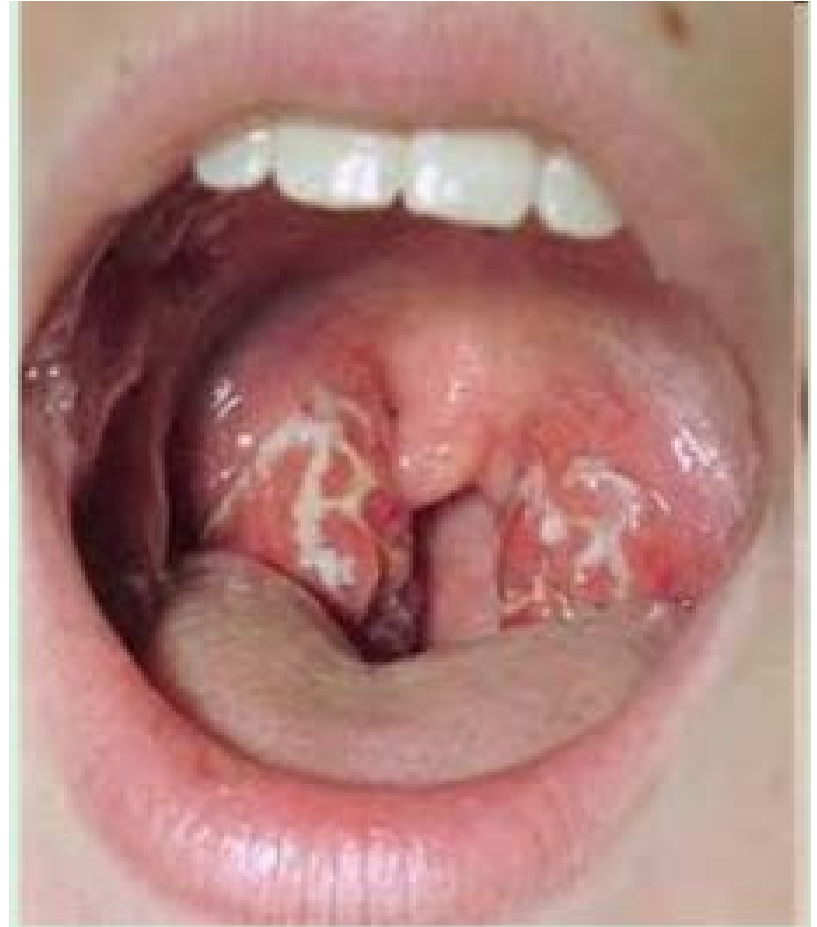# LYMPHOMAS

- **Cancers originating either from the lymphocytes in the lymph nodes or the lymphatic tissue in organs**
- **Risk factors -- HIV, HEPATITIS, EBV infections**



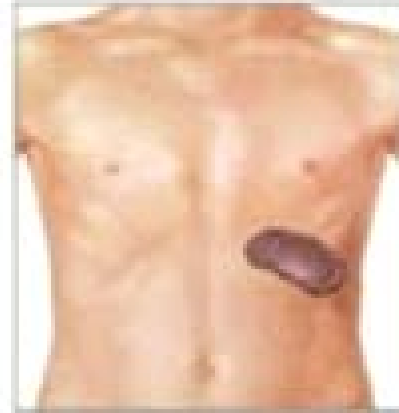
# TONSILLITIS

- **Infection of the pharyngeal tonsils**
- **Tonsils are swollen** ‘
- **Fever and pain during swallowing usually present**
- **Treatment** – surgical removal of tonsils (**TONSILLECTOMY**)

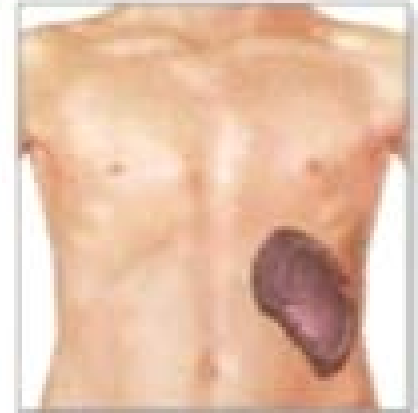


# SPLENOMEGALY

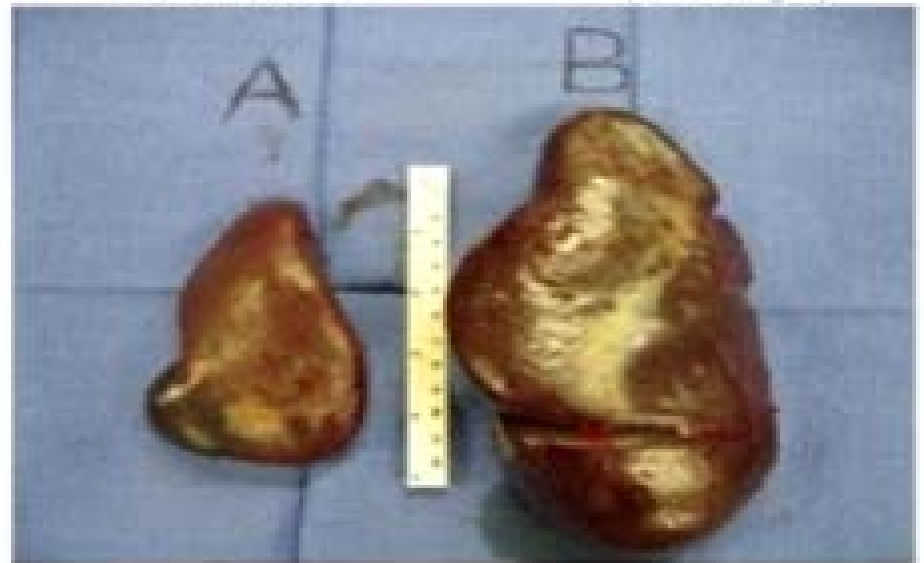- **Enlarged Spleen**
- **Various causes**



Normal spleen



Splenomegaly

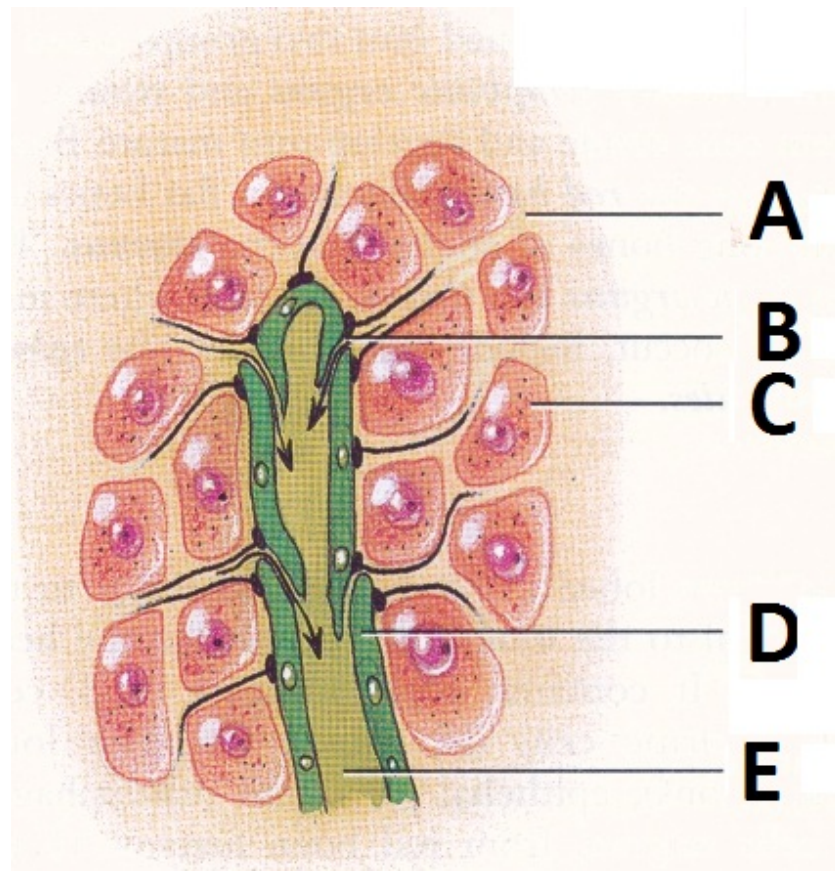


**LET'S REVISE SOME  
IMPORTANT FACTS**



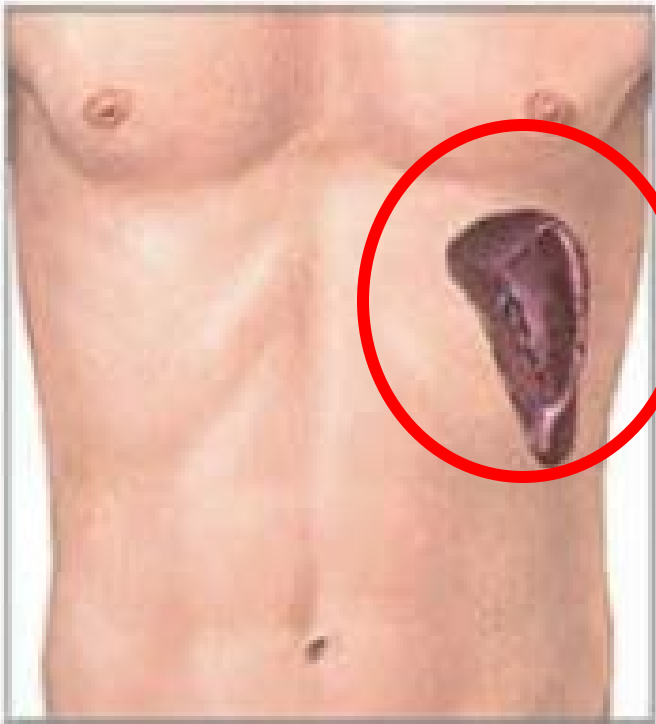# QUESTION. 1

Name the structures labelled A-E .



# QUESTION. 2

- I am a part of lymphatic system and protect the body by clearing worn out red cells and foreign bodies from the blood stream. Who am I?



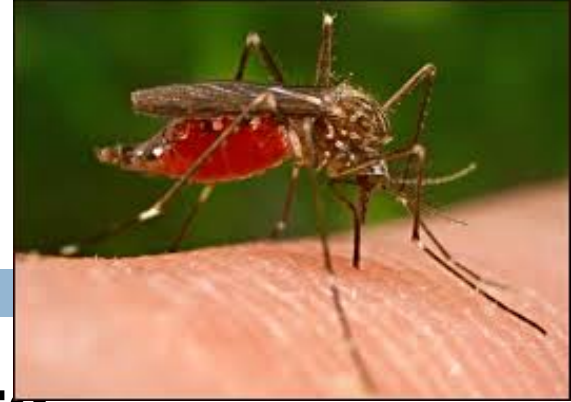- A. Thymus
- B. Palatine Tonsil
- C. Spleen
- D. Lymph node

# QUESTION. 3

**Which is the correct statement about the Lymphatic system?**

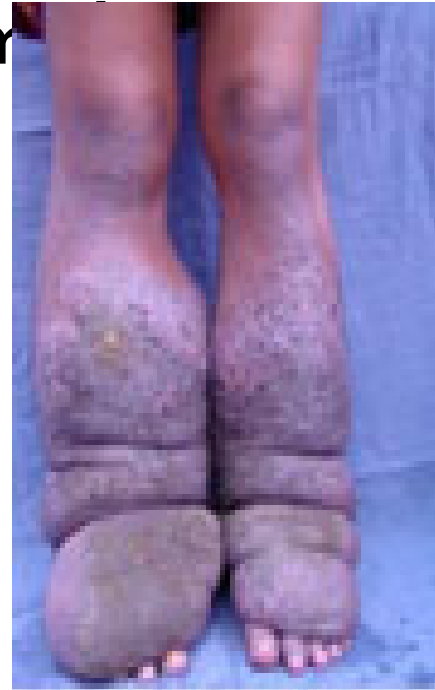- A. It Reabsorbs excess interstitial fluid and returns it to the venous circulation.**
- B. Transports dietary lipids through lacteals.**
- C. Helps in lymphocyte development, and the immune response.**
- D. All of the above**

# QUESTION. 4

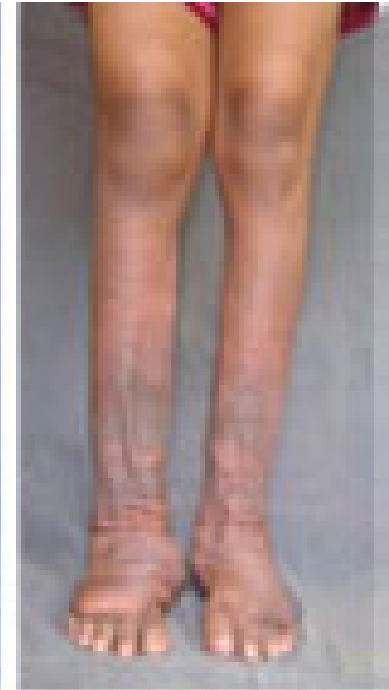

- Which disease caused by mosquito bite blocks the lymphatic drainage causing huge swelling of body parts (commonly lower limbs)

- A. Malaria
- B. Filaria
- C. Dengue
- D. Yellow fever



Before Treatment



After Treatment



# QUESTION. 5

- **Which of these is a primary lymphoid organ?**
  - A. Lymph Node**
  - B. Spleen**
  - C. Tonsil**
  - D. Bone Marrow**