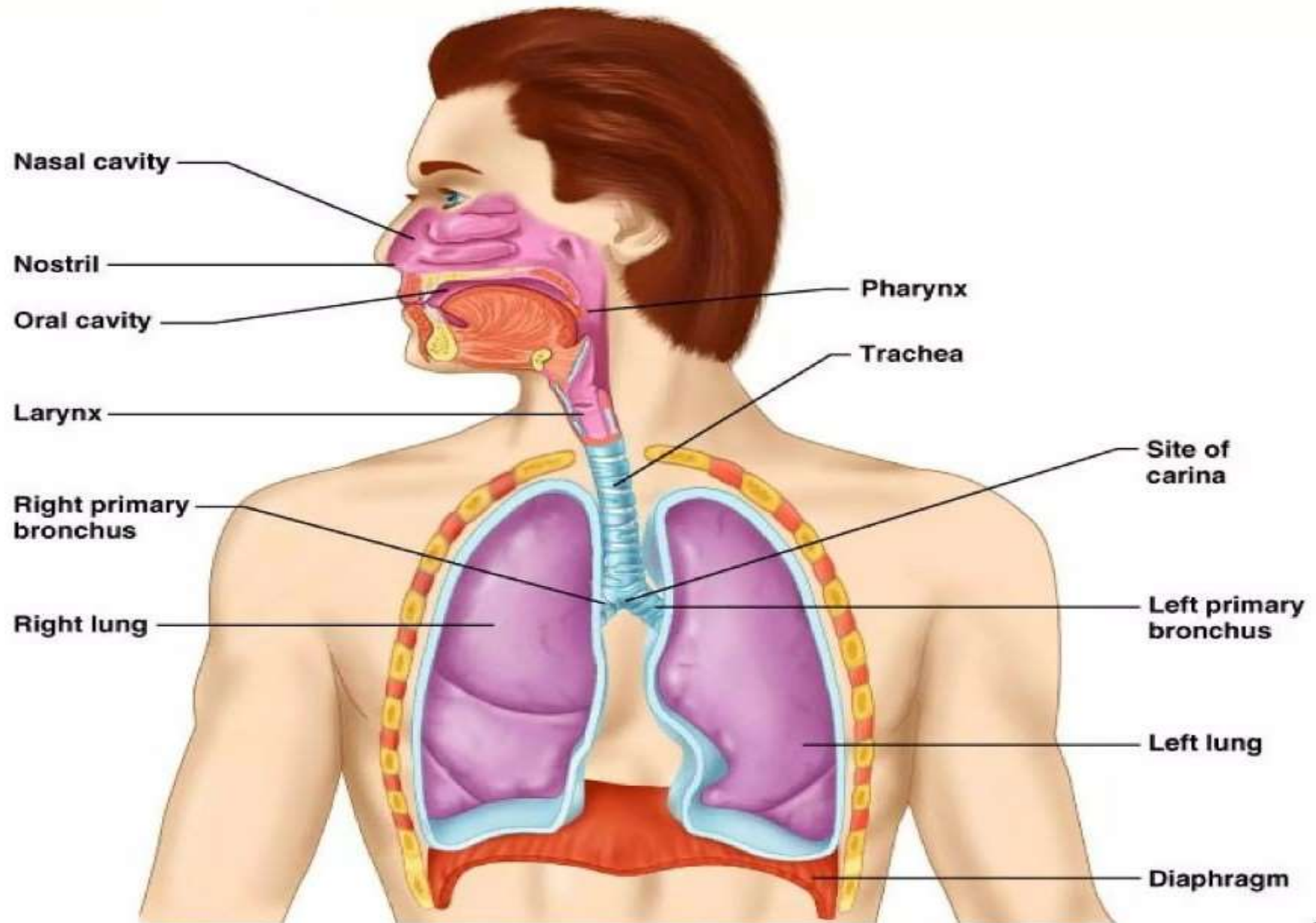


Respiratory System



Respiratory System Anatomy

- **Structurally**
 - Upper respiratory system
 - Nose, pharynx and associated structures
 - Lower respiratory system
 - Larynx, trachea, bronchi and lungs

Respiratory System

- **Functionally**
- Consists of the respiratory and conducting zones
- **Respiratory zone**
 - Site of gas exchange
 - Consists of bronchioles, alveolar ducts, and alveoli

Respiratory System

- **Conducting zone**
 - Provides rigid structures for air to reach the sites of gas exchange
 - Includes all other respiratory structures (e.g., nose, nasal cavity, pharynx, trachea)

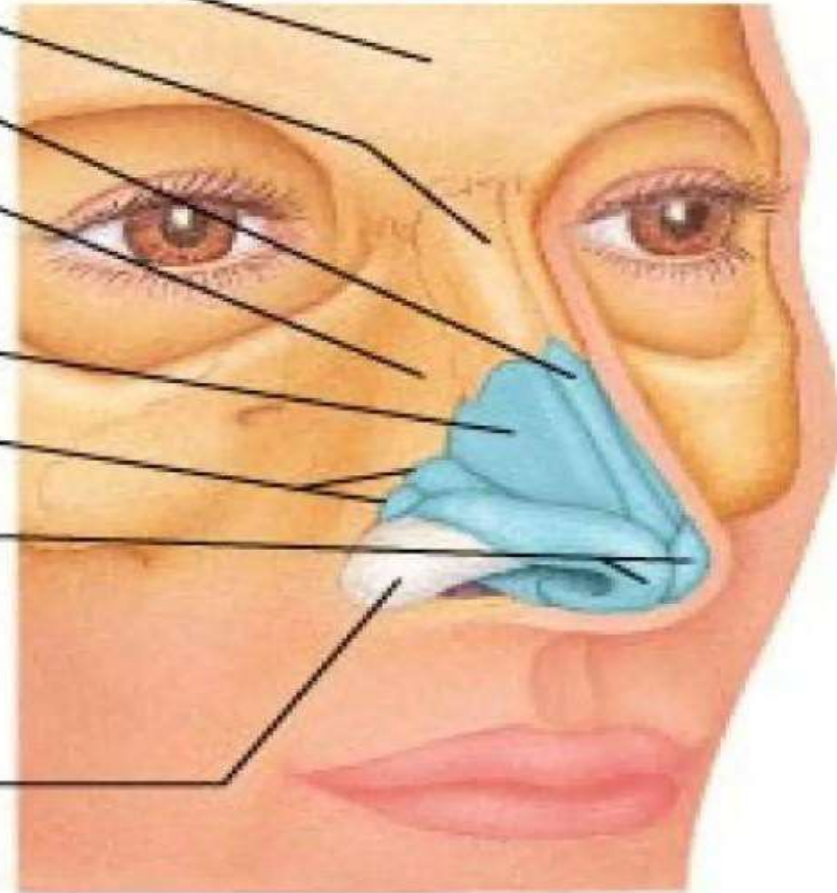
Structure of the Nose

- The nose is divided into two regions
 - The **external nose**
 - The **internal** nasal cavity

-
- The **external nose**, including the root, bridge, dorsum nasi, and apex
 - Philtrum – a shallow vertical groove inferior to the apex
 - The external nares (nostrils) are bounded laterally by the alae

Structure of the Nose

- Frontal bone
- Nasal bone
- Septal cartilage
- Maxillary bone
(frontal process)
- Lateral cartilage
- Lesser alar cartilages
- Greater alar
cartilages
- Dense fibrous
connective tissue



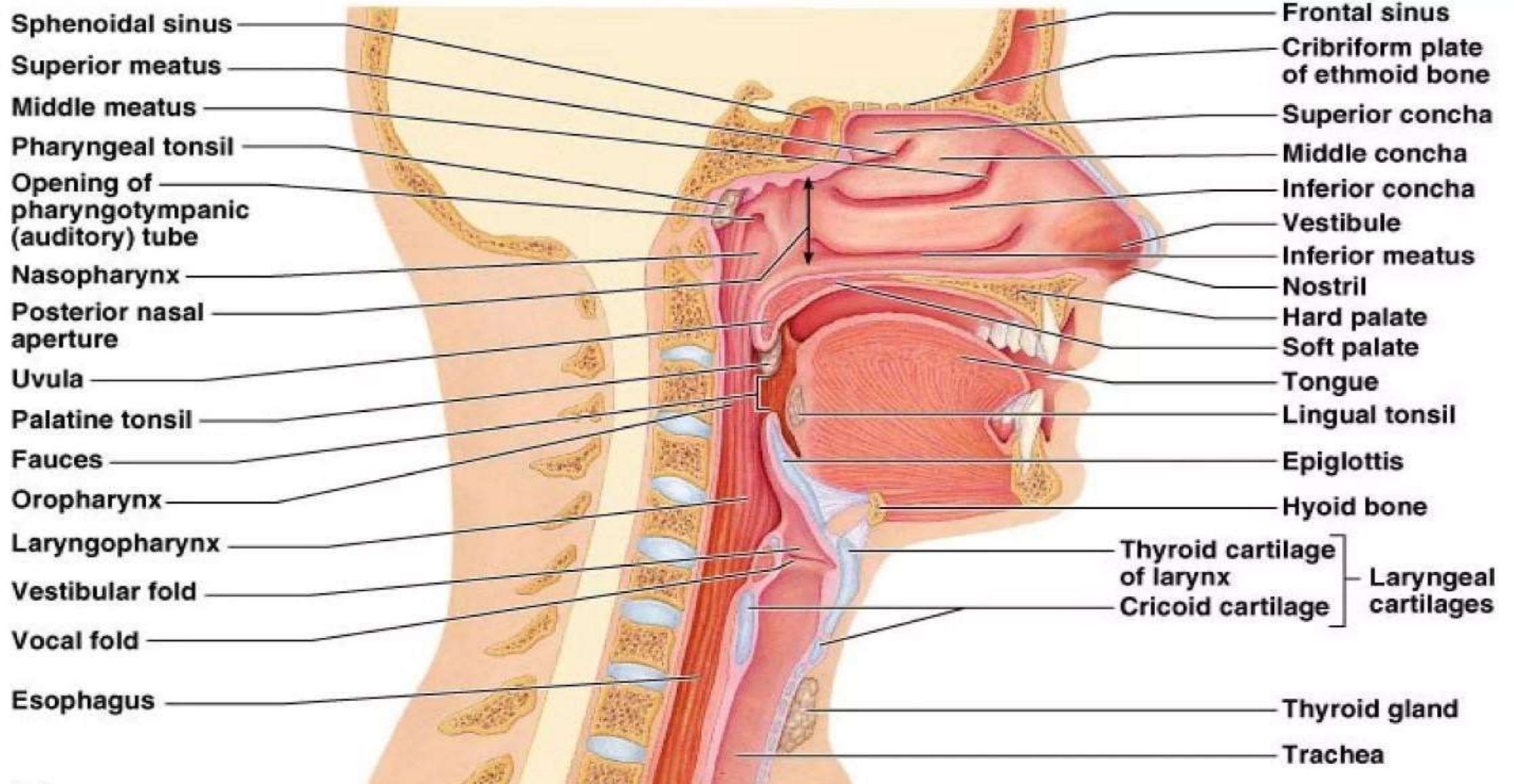
Nasal Cavity

- Lies in and posterior to the external nose
- Is divided by a midline nasal septum
- Opens posteriorly into the nasal pharynx via internal nares
- The ethmoid and sphenoid bones form the roof
- The floor is formed by the hard and soft palates

Nasal Cavity

- **Vestibule** – nasal cavity superior to the nares
 - Vibrissae – hairs that filter coarse particles from inspired air
- **Olfactory mucosa**
 - Lines the superior nasal cavity
 - Contains smell receptors

Nasal Cavity



Pharynx

- Funnel-shaped tube of skeletal muscle that connects to the:
 - Nasal cavity and mouth superiorly
 - Larynx and esophagus inferiorly
- Extends from the base of the skull to the level of the sixth cervical vertebra

Pharynx

- It is divided into three regions
 - Nasopharynx
 - Oropharynx
 - Laryngopharynx

Nasopharynx

- Lies posterior to the nasal cavity, inferior to the sphenoid, and superior to the level of the soft palate
- Strictly an air passageway
- Lined with **pseudostratified columnar epithelium**
- Closes during swallowing to prevent food from entering the nasal cavity
- The pharyngeal tonsil lies high on the posterior wall
- Pharyngotympanic (auditory) tubes open into the lateral walls

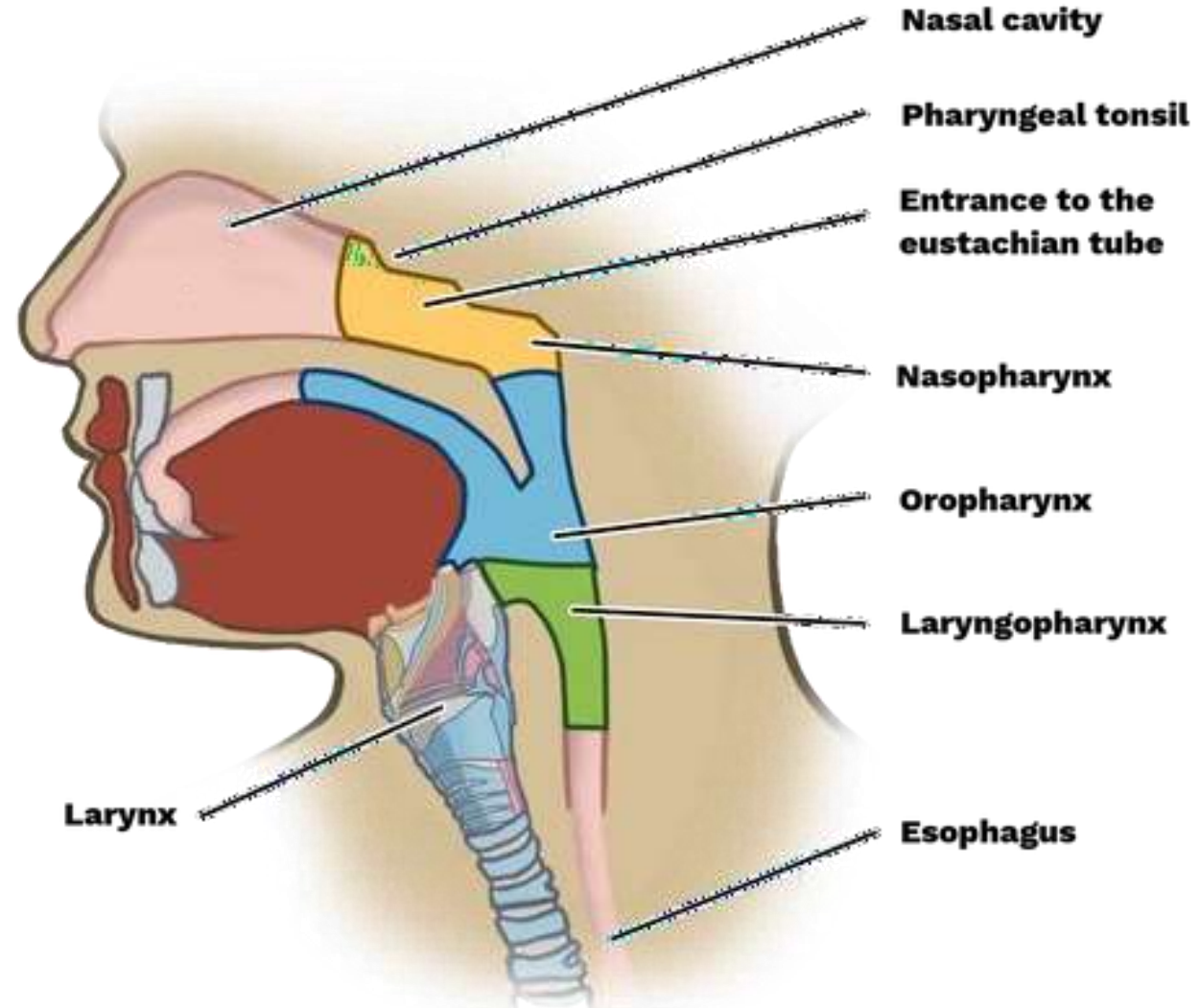
Oropharynx

- Extends inferiorly from the level of the soft palate to the epiglottis
- Serves as a common passageway for food and air
- The epithelial lining is protective **stratified squamous epithelium**
- **Palatine tonsils** lie in the lateral walls
- **Lingual tonsil** covers the base of the tongue

Laryngopharynx

- Serves as a **common passageway for food and air**
- Lies posterior to the upright epiglottis
- Extends to the larynx, where the respiratory and digestive pathways diverge

Pharynx



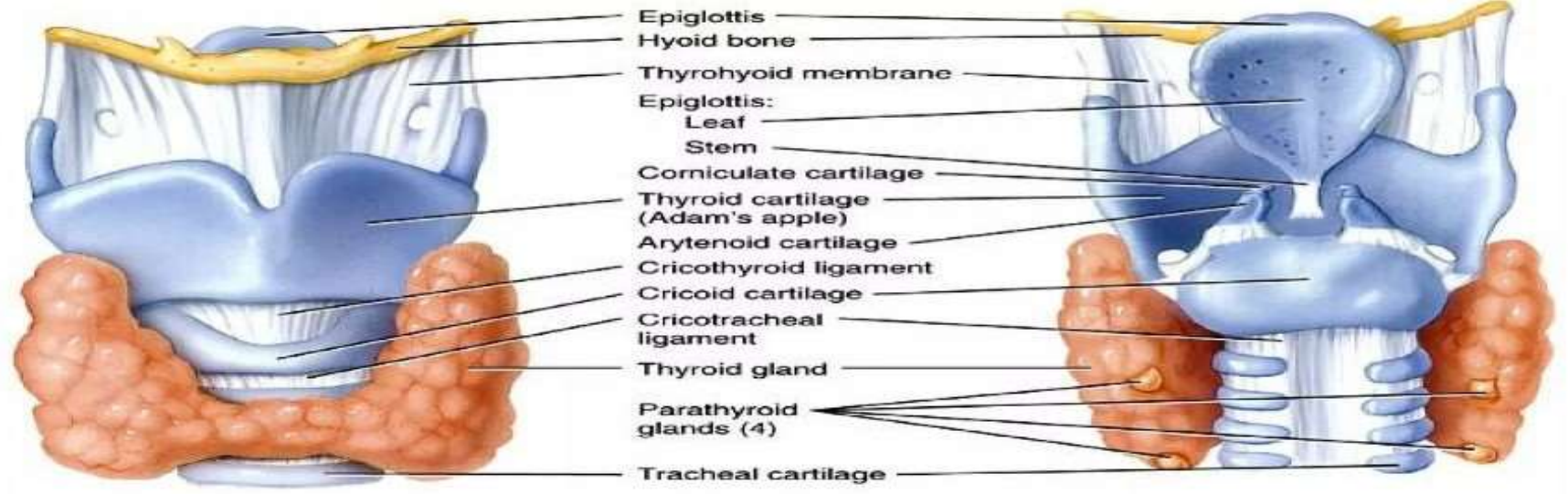
Larynx

- Short passageway connecting laryngopharynx with trachea
- Composed of 9 pieces of cartilage
 - **Thyroid cartilage** or Adam's apple
 - **Cricoid cartilage** hallmark for tracheotomy

Larynx



Larynx
Thyroid gland

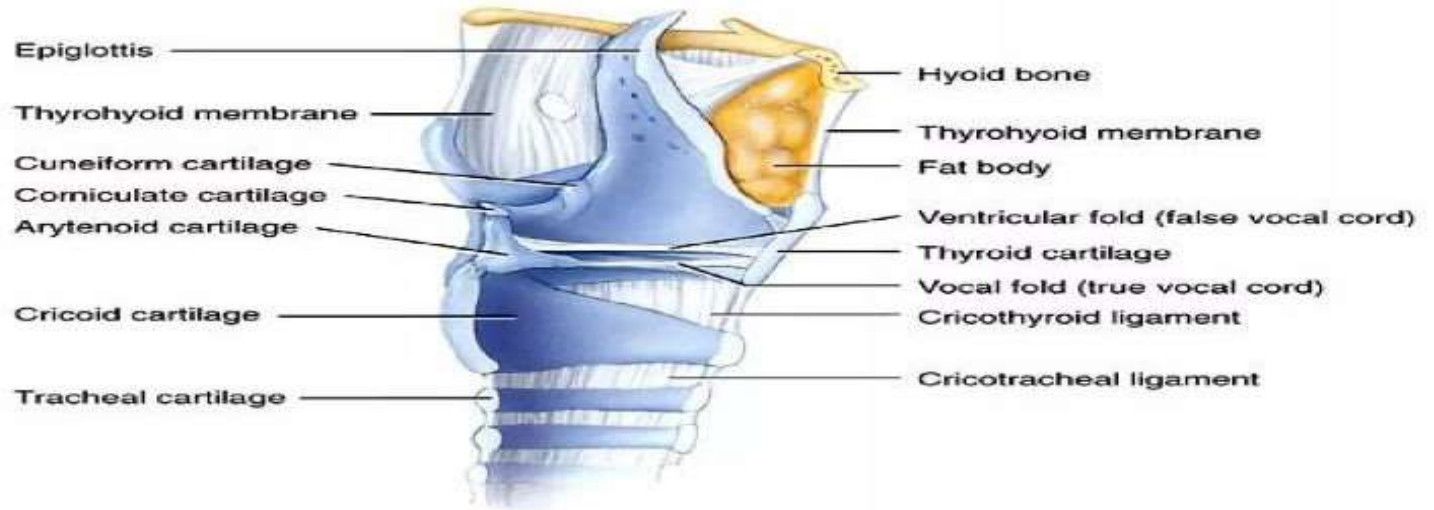


(a) Anterior view

(b) Posterior view



Sagittal plane



(c) Sagittal section

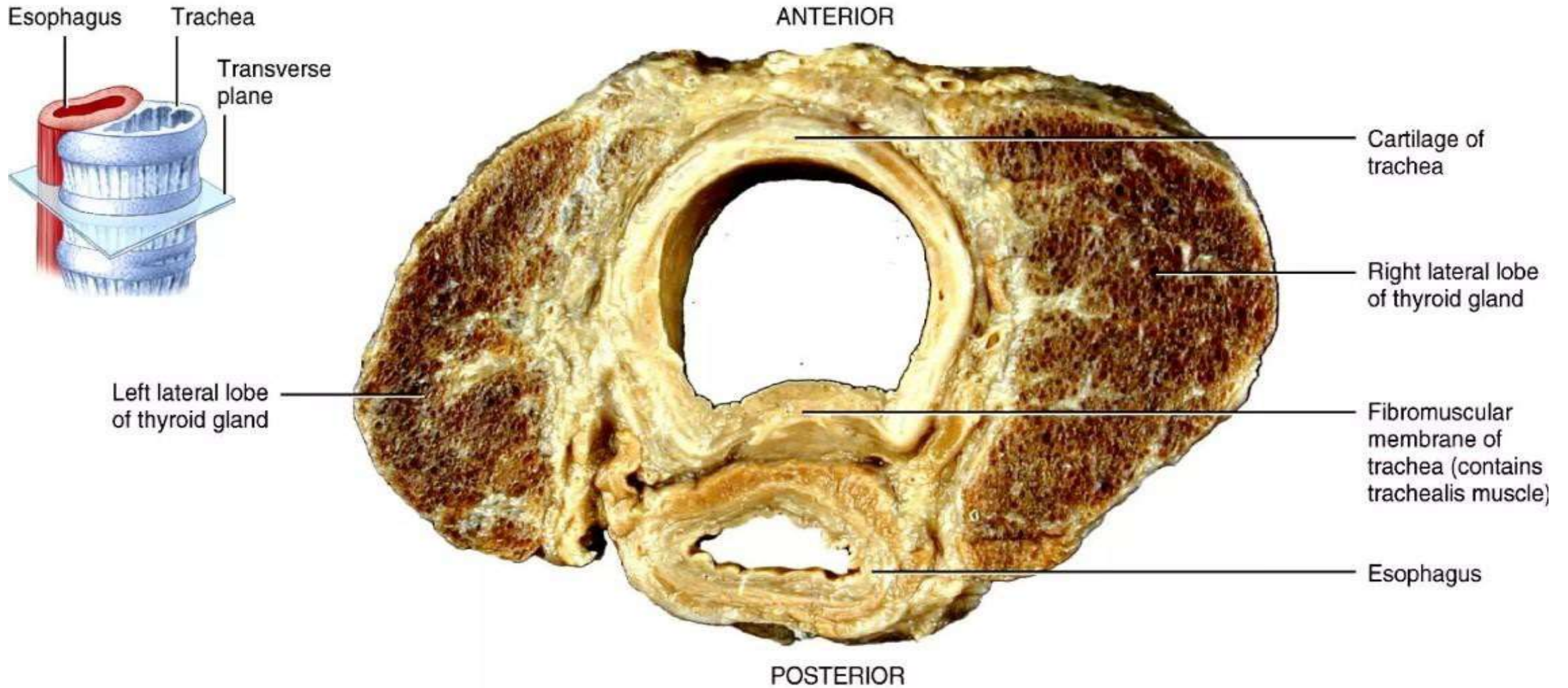
Larynx (Voice Box)

- Attaches to the hyoid bone and opens into the laryngopharynx superiorly
- Continuous with the trachea posteriorly

Trachea

- Flexible and mobile tube extending from the larynx into the mediastinum
 - Extends from larynx to superior border of T5
 - Divides into right and left primary bronchi

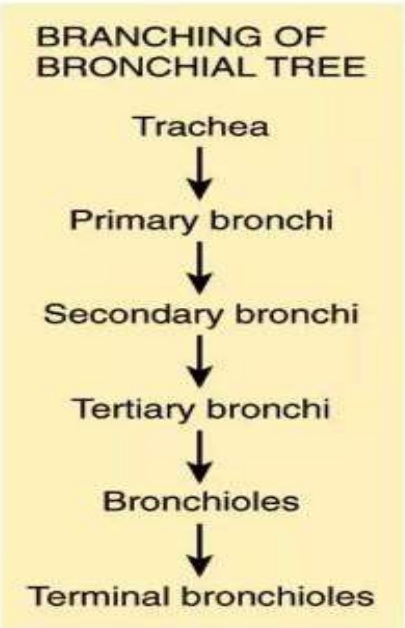
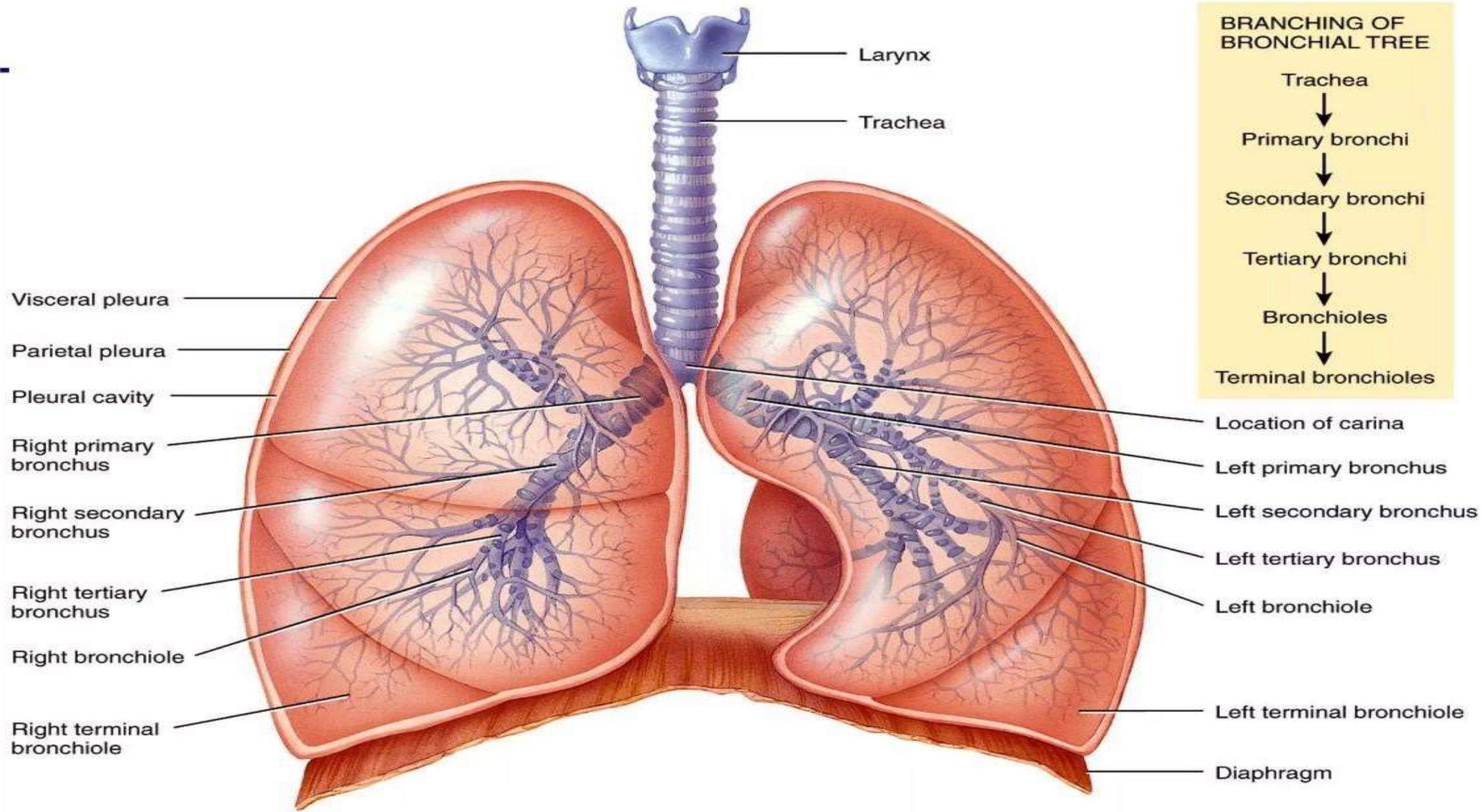
Location of Trachea



Superior view of transverse section of thyroid gland, trachea, and esophagus

Bronchi

- Right and left primary bronchus goes to right and left lungs
- Carina – internal ridge
 - Most sensitive area for triggering cough reflex
- Divide to form bronchial tree
 - Secondary lobar bronchi (one for each lobe), tertiary (segmental) bronchi, bronchioles, terminal bronchioles



Visceral pleura
 Parietal pleura
 Pleural cavity
 Right primary bronchus
 Right secondary bronchus
 Right tertiary bronchus
 Right bronchiole
 Right terminal bronchiole

Larynx
 Trachea

Location of carina
 Left primary bronchus
 Left secondary bronchus
 Left tertiary bronchus
 Left bronchiole
 Left terminal bronchiole
 Diaphragm

Lungs

- Cardiac notch (impression) – cavity that accommodates the heart
- Left lung – separated into upper and lower lobes by the oblique fissure
- Right lung – separated into three lobes by the oblique and horizontal fissures
- There are 10 bronchopulmonary segments in each lung

Lungs

- Separated from each other by the heart and other structures in the mediastinum
- Cardiac notch – heart makes left lung 10% smaller than right

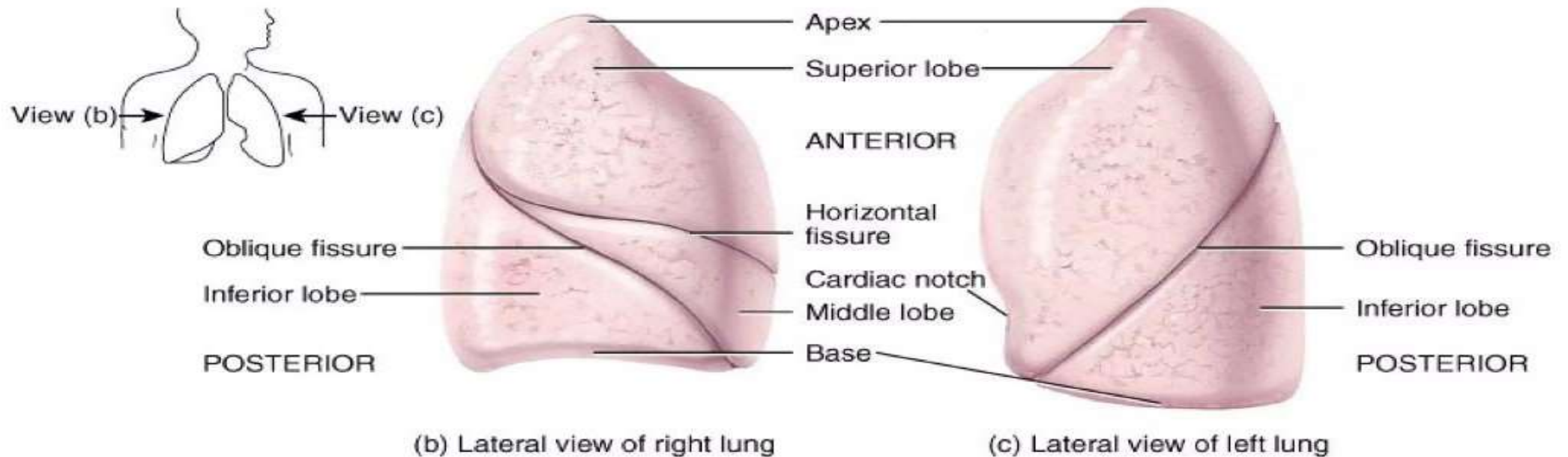
Gross Anatomy of the Lungs

- Lungs occupy all of the thoracic cavity except the mediastinum
 - Root – site of vascular and bronchial attachments
 - Costal surface – anterior, lateral, and posterior surfaces in contact with the ribs
 - Apex – narrow superior tip
 - Base – inferior surface that rests on the diaphragm



Gross Anatomy of Lungs

- Base, apex (cupula), costal surface, cardiac notch
- Oblique & horizontal fissure in right lung results in 3 lobes
- Oblique fissure only in left lung produces 2 lobes



Pleurae

- Thin, double-layered serosa
- **Parietal pleura**
 - **Covers the thoracic wall** and superior face of the diaphragm
 - Continues around heart and between lungs

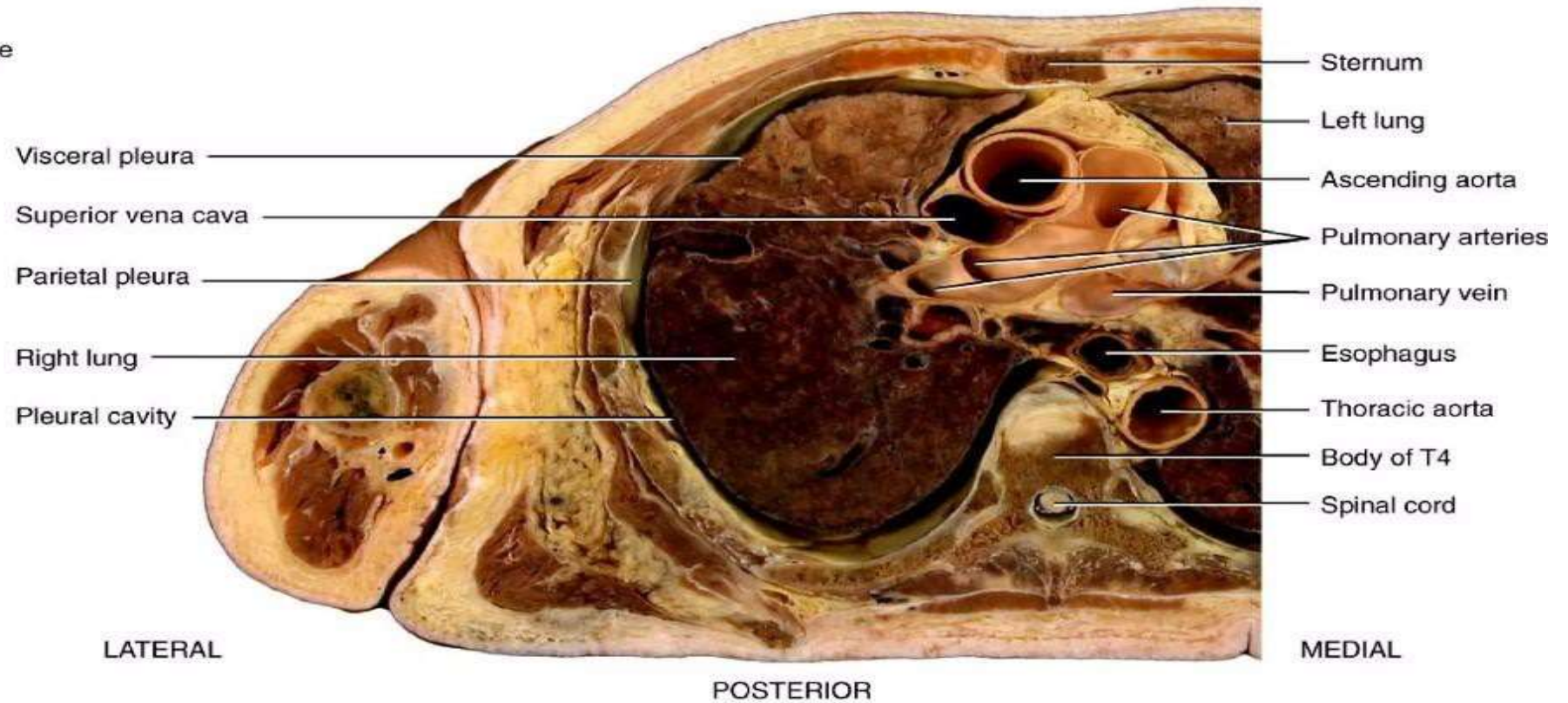
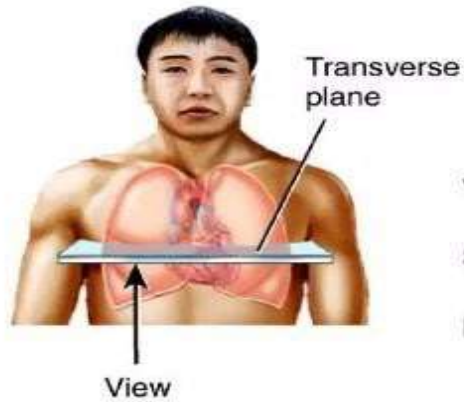
Pleurae

- Visceral, or pulmonary, pleura
 - Covers the external lung surface
 - Divides the thoracic cavity into three chambers
 - The central mediastinum
 - Two lateral compartments, each containing a lung

Pleura

- Each lung enclosed by double-layered pleural membrane
 - Parietal pleura – lines wall of thoracic cavity
 - Visceral pleura – covers lungs themselves
- Pleural cavity is space between layers
 - Pleural fluid reduces friction, produces surface tension (stick together)

Relationship of the Pleural Membranes to Lungs



Inferior view of a transverse section through the thoracic cavity showing the pleural cavity and pleural membranes

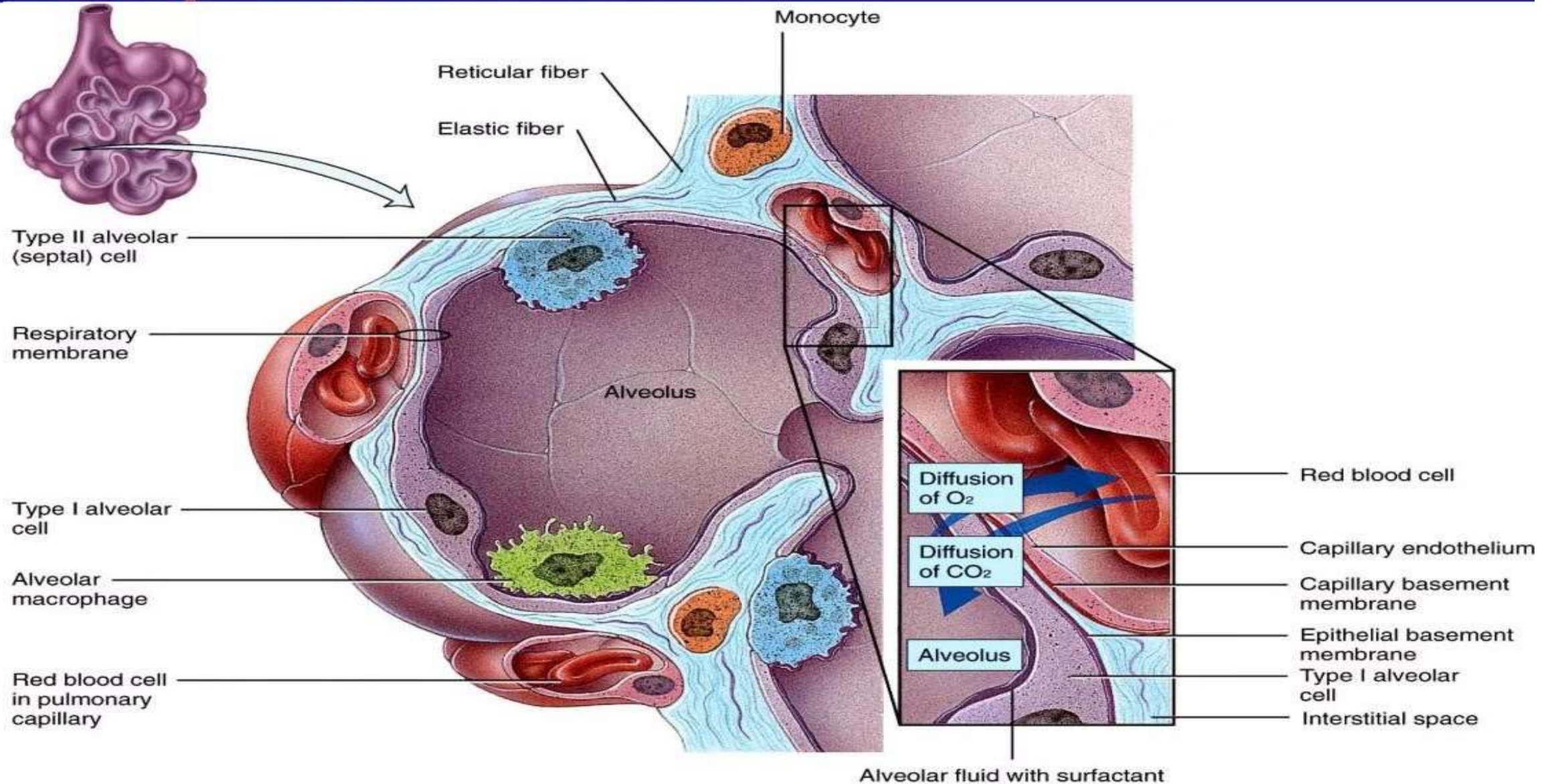
Alveoli

- Cup-shaped outpouching
- Alveolar sac – 2 or more alveoli sharing a common opening

Alveolus

- Respiratory membrane
 - Alveolar wall – type I and type II alveolar cells
 - Epithelial basement membrane
 - Capillary basement membrane
 - Capillary endothelium
 - Very thin – only 0.5 μm thick to allow rapid diffusion of gases

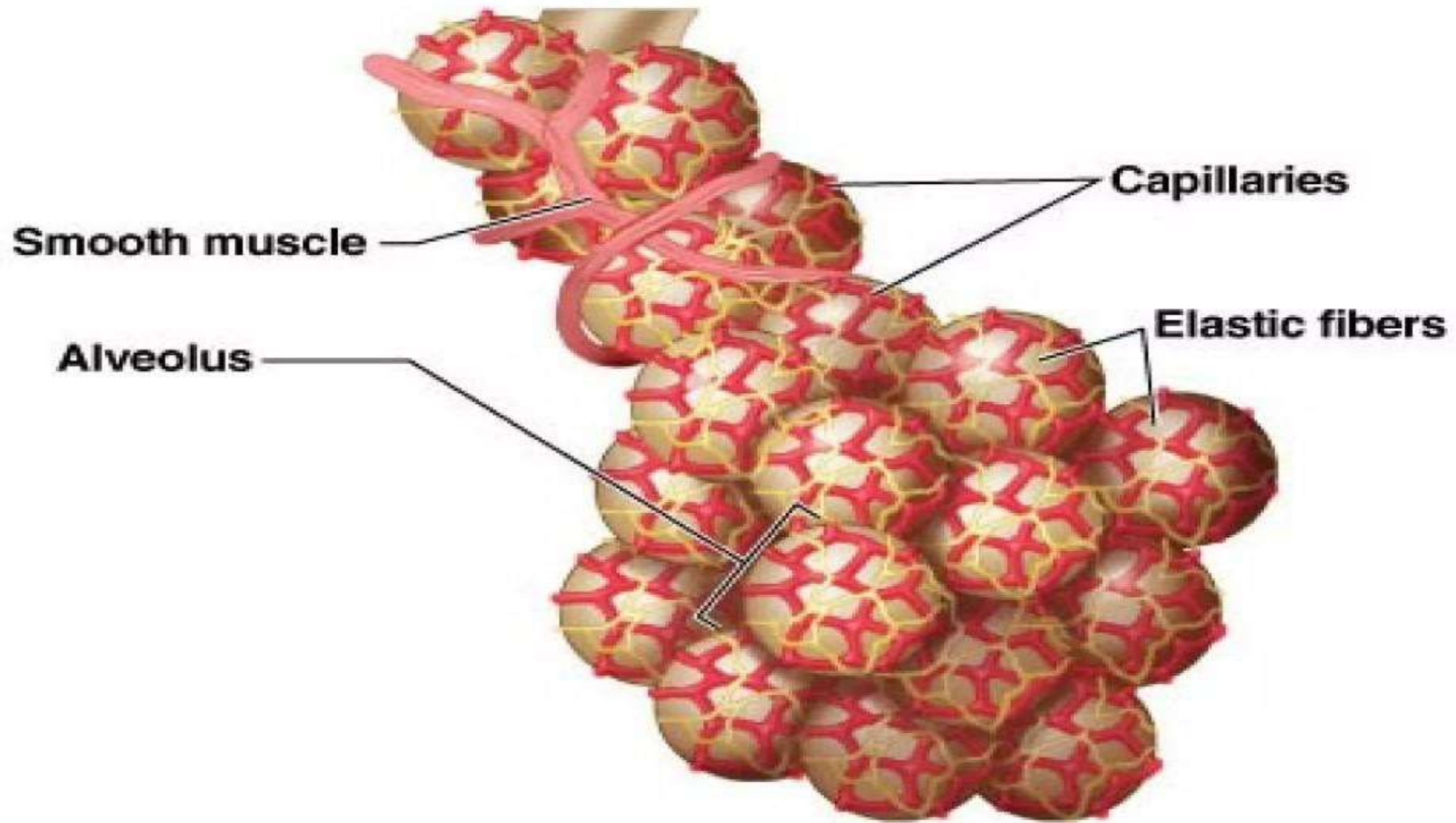
Components of Alveolus



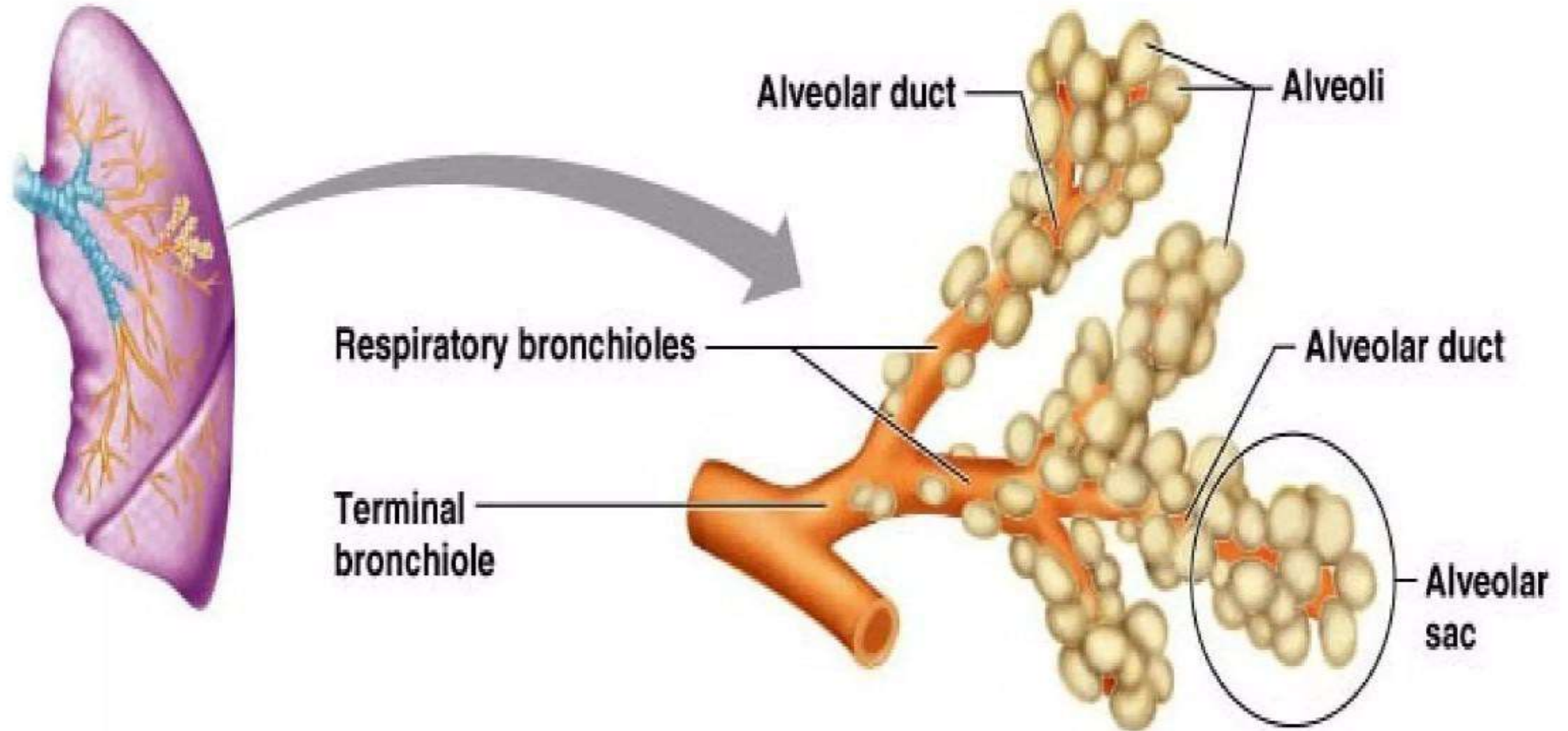
(a) Section through an alveolus showing its cellular components

(b) Details of respiratory membrane

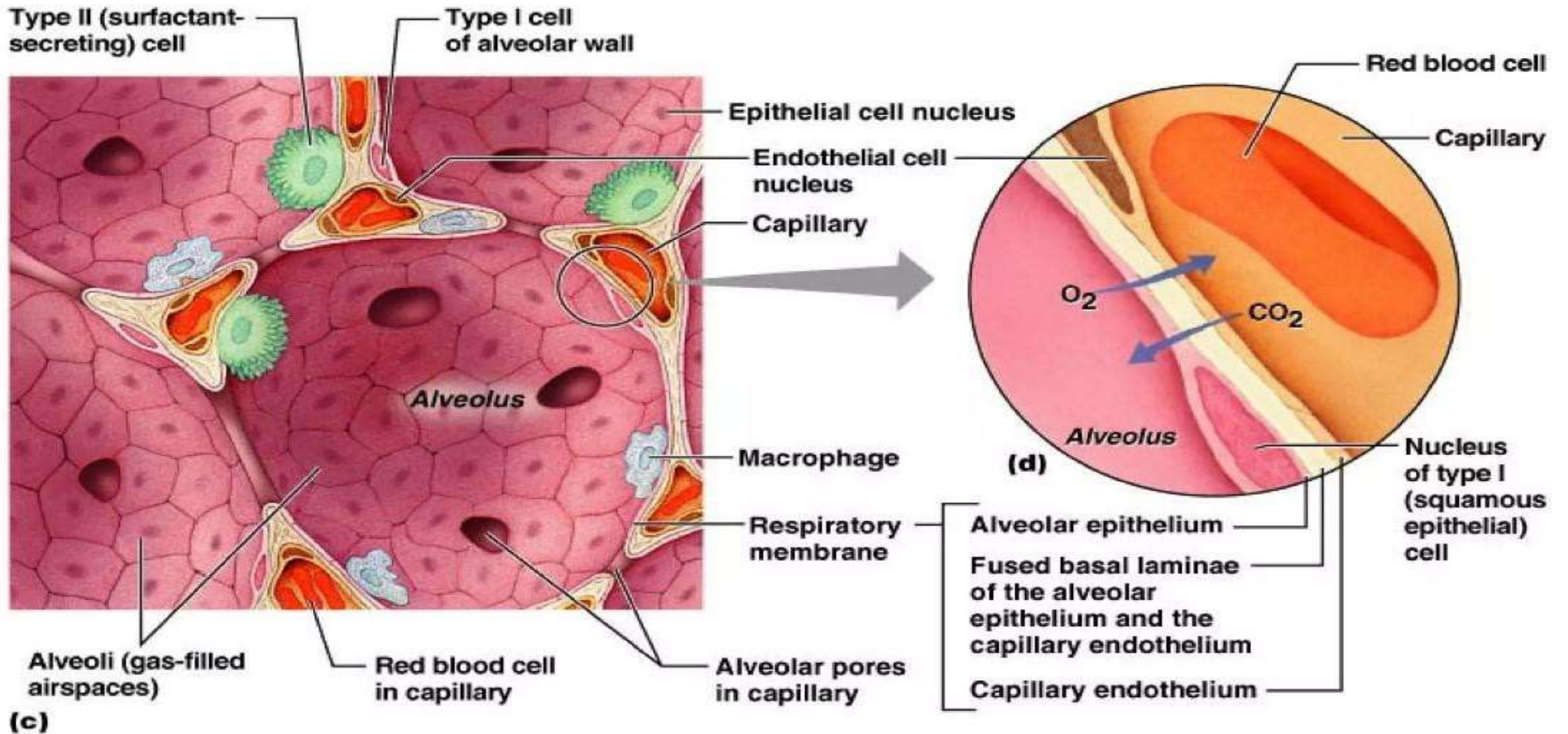
Respiratory Membrane



Respiratory Zone



Respiratory Membrane



THANK YOU